



## 61-YEARS-OLD FEMALE WITH MOYAMOYA SYNDROME: A CASE REPORT

Azmi Farah Fairuzya<sup>1\*</sup>, Martha Oktavia Dewi Savitri<sup>1</sup>, Subandi<sup>1</sup>, Iqbal Imanuddin<sup>1</sup>, Andry Nur Wahyu Putra Romadhoni<sup>1</sup>, Tomohiro Hosoya<sup>2</sup>

\*Correspondence: [fairuzyazmi@gmail.com](mailto:fairuzyazmi@gmail.com)

<sup>1</sup>Department of Neurology, Faculty of Medicine, Universitas Sebelas Maret, Surakarta, Indonesia

<sup>2</sup>Department of Neurosurgery, Faculty of Medicine, Tottori University, Tottori, Japan

### Article History:

Received: January 15, 2024

Accepted: February 29, 2024

Published: January 1, 2025

### Cite this as:

Fairuzya AF, Savitri MOD, Subandi, Imanuddin I, Romadhoni ANWP, Hosoya T. A 61-Years-Old Female with Moyamoya Syndrome: A Case Report. *Magna Neurologica*. 3(1) January 2025: 1-4. 10.20961/magnaneurologica.v2i2.1119

### ABSTRACT

**Background:** Moyamoya vasculopathy (MMV), like Moyamoya disease (MMD) and Moyamoya syndrome (MMS), is a rare chronic cerebrovascular angiopathy, especially in elderly patients. The incidence onset of MMV was unique with bimodal peak age: 5-10 years old and 25-49 years old.

**Case:** A 61-year-old female complained of sudden onset left-sided hemiparesis one month before admission, headache, and forgetfulness. She had a history of diabetes mellitus for 3 years—neurological physical examination found left hemiparesis with motoric strength 4/5. Laboratory findings are unremarkable. A brain MRI with contrast showed infarcts in subcortical regions. Her cerebral DSA examination suggested diffuse multiple stenosis in the anterior circulation and total occlusion of the left external and internal carotid artery. “Puff of smoke” and “champagne-bottle-like neck sign” were found in DSA imaging, typical signs of MMD. She received aspirin 80 mg as her secondary prevention of another stroke event.

**Discussion:** Our study showed MMV cases at elderly onset, which is similar to a prior small study with a mean age of 60 years old. Previous studies mentioned hypertension (44%) and diabetes mellitus (16%) were found in older MMD patients. The patient was given aspirin 80mg daily. Precautions in this case include taking lifelong antiplatelet, managing diabetes mellitus, and implementing lifestyle modification. This treatment approach was directed to lower the attendant risk of ischemic stroke.

**Conclusion:** We report a case of MMV, which was considered a rare case and a cause of stroke event. The management of this case was directed to control the coexisting condition of ischemic stroke using antiplatelet drugs and risk factor management.

**Keywords:** aspirin, DSA, elderly, moyamoya



This is an open access article distributed under the terms of the Creative Commons Attribution-4.0 International License

## Introduction

Adult Moyamoya disease and syndrome are uncommon conditions with substantial morbidity and mortality.<sup>1</sup> Moyamoya Disease (MMD) is a rare cerebrovascular condition characterized by progressive occlusion and stenosis of the terminal portion of the internal carotid artery and its proximal branches. This narrowing leads to the development of an abnormal, fragile network of dilated collateral vessels and perforators at the base of the brain, which are prone to rupture or insufficient blood flow. As the disease progresses, these compensatory vessels

become increasingly fragile, contributing to a higher risk of ischemic or hemorrhagic events.

This disease frequently occurs in pediatric and young adult patients and may lead to ischemic or hemorrhagic stroke, headache, epilepsy, or Transient Ischemic Attack (TIA).<sup>1,2</sup> There exist few epidemiological studies on moyamoya disease worldwide. Japanese studies reported that the prevalence of MMD was 3.16 per 100000 and an estimated incidence of 0.35 per 100000,<sup>3</sup> but the epidemiological data on MMD in Indonesia is still lacking.

Headache in Moyamoya vasculopathy (MMV) has characteristics such as migraine-type headaches or tension-type headaches, which are more common (> 50%) in migraine-type headaches.<sup>4,5</sup> Moyamoya Syndrome (MMS) is a condition when diagnostic criteria of MMD and other comorbidities associated with vasculopathy emerge in a patient.<sup>1</sup> Digital Subtraction Angiography (DSA) is the gold standard for diagnosing MMV, and the Suzuki Classification has been used to characterize the formation of moyamoya collateral. Surgical treatment for MMV consists of revascularization procedures.<sup>1</sup> This study aims to report the rare case of MMV in elderly patients with ischemic stroke.

## Case Report

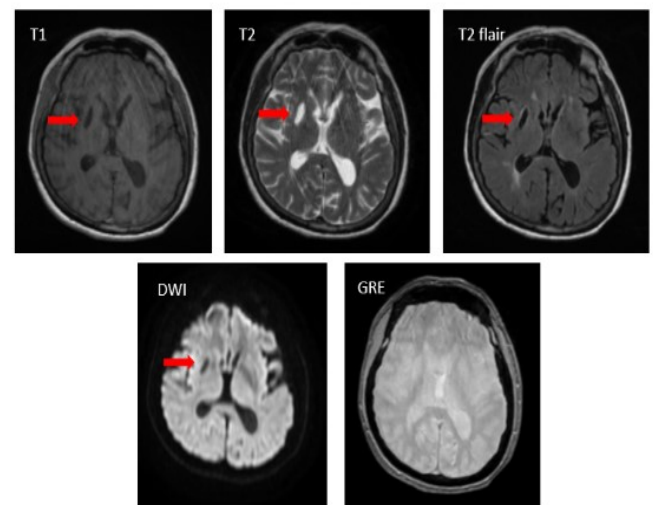
A 61-year-old female with left-sided hemiparesis one month before admission. A left-sided throbbing headache persisted for three days. The family said the patient recently forgot things quickly. No vomiting, seizures, loss of consciousness, slurred speech, or facial drooping were reported. There has been no previous history of this condition, and the patient had diabetes for 3 years. The patient's family had no similar condition; hypertension and diabetes were denied. His relatives brought him to a private hospital for an obstructive stroke. The patient was discharged after seven days in the hospital. The patient was referred to a Dr. Moewardi Hospital neurologist for DSA after the symptoms did not improve.

During the physical examination, the patient was fully conscious with GCS E4V5M6. The blood pressure was also measured to be 130/80 mmHg, pulse rate was 88 beats per minute, respiration rate was 18 breaths per minute, and body temperature was 36.70 C. The neurological examination revealed the presence of cranial nerve XII paralysis, characterized by lateral deviation of the tongue upon extension. Additionally, the examination indicated a motor strength of 4/5 in the left limb, along with a positive Babinski reflex on the left leg. The assessment of cerebral function, meningeal signs, physiological reflexes, sensory perception, and autonomic system demonstrate values within the expected range.

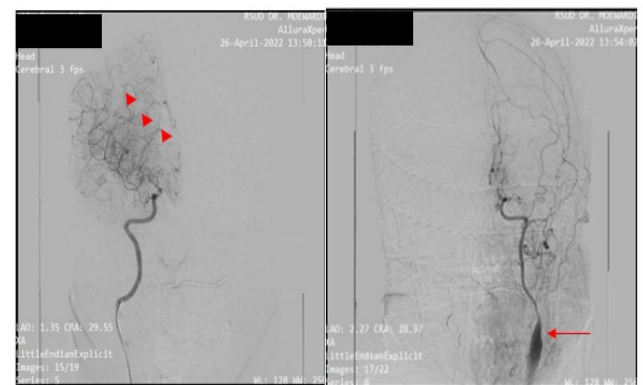
The laboratory findings were unremarkable. The patient underwent a brain magnetic resonance imaging (MRI) scan that showed multiple subcortical infarcts (Figure 1). The patient also underwent cerebral digital subtraction angiography (DSA) and was diagnosed with diffuse multiple stenosis in the anterior circulation, affecting the internal carotid artery (ICA), anterior cerebral artery (ACA), and middle cerebral artery (MCA) on both sides. Total occlusion of left internal carotid artery (LICA) with collateral from posterior

circulation and left external carotid artery (LECA). The DSA findings also suggested a champagne bottle-like neck sign appearance at ICA in left CCAG, a typical sign of MMD (Figure 2). The diagnosis of Moyamoya syndrome was established based on a thorough evaluation of the patient's clinical presentation, combined with detailed findings from supporting investigations, including imaging studies and relevant laboratory tests.

Subsequently, she was discharged from the hospital after four days. She prescribed a treatment regimen consisting of paracetamol 1000 mg q12h (for headache), citicoline 500mg q12h, aspirin 80mg q24h, atorvastatin 40mg q24h, and metformin 500mg q8h. During the one-year follow-up, a recurrence of the stroke was not reported.



**Figure 1.** MRI Brain Contrast suggested subcortical infarct (red arrow). (Source: Radiology Unit of Dr. Moewardi Hospital Surakarta)



**Figure 2.** Cerebral Digital Subtraction Angiography. The left image showed a finding of a “puff of smoke” (▲), and the right image showed a champagne bottle-neck sign appearance at ICA in the left CCAG (←), typical signs of MMD. (Source: Radiology Unit of Dr. Moewardi Hospital Surakarta). ICA: Internal Carotid Artery, CCAG: Common Carotid Artery Angiogram

## Discussion

Moyamoya syndrome (MMS) and moyamoya disease (MMD) are rare chronic cerebrovascular vasculopathy characterized by progressive occlusion or stenosis of internal carotid arteries (ICA) and their branches. The term “Moyamoya” was from the Japanese word for “hazy,” which describes a vessel sprouting like a “puff of cigarette smoke” as compensation for stenotic angiopathy.<sup>6,7</sup> By definition, MMS and MMD are different. We defined it as MMD in cases with unknown associated risk factors. The typical structural arterial changes were bilateral involvement in MMD and unilateral findings in MMS.<sup>8</sup> Based on a new scientific statement from AHA/ASA (2023), we use the term Moyamoya vasculopathy (MMV) for a nonspecific referral of either MMD or MMS.<sup>1</sup>

The incidence onset of MMV was unique with bimodal peak age: 5-10 years old and 25-49 years old.<sup>6</sup> Our case presented MMV in older people after their four decades of life. This finding was different from previous known epidemiology. However, our finding was similar to a prior small study from Gupta et al. (2016), which presented eight patients with a median age of 60.<sup>9</sup> A History of uncontrolled hypertension and diabetes mellitus was obtained from the patient. These classic stroke risk factors were only found in minor cases.<sup>6</sup> From a previous case-control study by Ge et al. (2020), hypertension (44%) and diabetes mellitus (16%) were found in older MMD patients.<sup>10</sup> Associated conditions of MMS, such as sickle cell disease, neurofibromatosis-1, Down’s syndrome, had not been furtherly evaluated yet in our case, but we can exclude Down’s syndrome and neurofibromatosis-1 based on clinical manifestation.

MMV may present with various clinical manifestations and can be divided into ischemic and hemorrhagic manifestations.<sup>1,11</sup> In our case, the patient presented with sudden-onset left-sided hemiparesis and was diagnosed with ischemic stroke. In the adult population, ischemic attacks, hemorrhagic events, or both are frequent. Still, ischemic events are more frequent in pediatric patients.<sup>6,12</sup> Symptoms of cerebral ischemia in MMV are associated with arterial territory, ICA, and MCA. Conventional CT and nonquantitative MRI play a limited role in diagnosing and evaluating the MMV, but they can at least provide clues to make a preliminary diagnosis.<sup>13</sup> Patient’s DSA examination suggested diffuse multiple stenosis at anterior circulation (bilateral ICA, ACA, MCA) with pathognomonic angiographic finding “puff of smoke” at right-sided arterial circulation.<sup>14</sup> Proposed imaging diagnostic criteria for MMV by DSA, the required findings are stenosis or occlusion in the arteries centered on the terminal portion of ICA and

Moyamoya vessels in the vicinity of the occlusive or stenotic lesions in the arterial phase.<sup>14</sup> “Champagne bottle-neck sign,” a sharp narrowing of proximal ICA less than half the diameter of CCA, was often found in 74% of patients with MMD.<sup>15,16</sup> All these required imaging findings were found in our patient to establish the Moyamoya diagnosis.

The treatment approach was directed to lower the attendant risk of ischemic and hemorrhagic stroke. Our patient received oral therapy with antiplatelet aspirin 80 mg daily. This therapy was based on AHA/ASA 2021 Guideline Recommendation in patients with MMD and a history of ischemic stroke or TIA; the use of antiplatelet therapy, typically aspirin monotherapy, for the prevention of ischemic stroke or TIA may be reasonable.<sup>17</sup> MMV can cause hemodynamic insufficiency, progressive steno-occlusion of intracranial arteries, and intraluminal micro-thromboembolism. The use of antiplatelets is expected to counter that pathology.<sup>18</sup> Imaging reevaluation using MRI might be considered for detecting microbleeds to predict and prevent future bleeding.<sup>19</sup> In our case, there is an additional risk factor, which is diabetes mellitus. Control management of this vascular risk factor was essential to reduce the risk of stroke recurrence.<sup>20</sup> Precautions in this case include taking lifelong antiplatelet, managing diabetes mellitus, and implementing lifestyle modification.

## Conclusion

We report a case of MMV, which is considered a rare case in Indonesia. MMV might be the risk factor for stroke events in this patient. The management of this case was directed to control the coexisting condition of ischemic stroke. Oral antiplatelet and risk factor management were applied as secondary prevention of stroke events.

## References

1. Gonzalez NR, Amin-Hanjani S, Bang OY, Coffey C, Du R, Fierstra J, et al. Adult Moyamoya disease and syndrome: Current perspectives and future directions: A scientific statement from the American Heart Association/American Stroke Association. *Stroke*; 2023;54(10): e465-e479
2. Zhang H, Zheng L, Feng L. Epidemiology, diagnosis and treatment of moyamoya disease. *Exp Ther Med*; 2019. 17(3):1977-1984.
3. Kim JS. Moyamoya Disease: Epidemiology, Clinical Features, and Diagnosis. *Journal of Stroke*; 2016. 18(1):2-11

4. Kraemer M, Lee SI, Ayzenberg I, Schwitalla JC, Diehl RR, Berlitz P, et al. Headache in caucasian patients with Moyamoya angiopathy - a systematic cohort study. *Cephalalgia*; 2017. 37(5):496-500.
5. Gao B, Kang K, Zhang J, Zhang D, Zhao X. Clinical characteristics and long-term outcome of headaches associated with moyamoya disease in the Chinese population—a cohort study. *Frontiers in Neurology*; 2020: 605636
6. Vetrano IG, Bersano A, Canavero I, Restelli F, Raccuia G, Ciceri EF, et al. Characteristics of moyamoya disease in the older population: Is it possible to define a typical presentation and optimal therapeutical management? *Journal of Clinical Medicine*; 2021. 10:2287.
7. Demartini Jr. Z, Teixeira BCA, Koppe GL, Gatto LAM, Roman A, Munhoz RP. Moyamoya disease and syndrome: a review. *Radiologia Brasileira*; 2022. 55(1):31-37.
8. Berry JA, Cortez V, Toor H, Saini H, Siddiqi J. Moyamoya: An Update and Review. *Cureus*; 2020. 12(10):e10994
9. Gupta R, M Moore J, Adeeb N, Griessenauer CJ, Patel AS, Chua MH, et al. Clinical presentation, progression, and treatment outcomes of Moyamoya disease in the elderly. *Acta Neurochirurgica*; 2016. 158(12):2409-2414.
10. Ge P, Zhang Q, Ye X, Liu X, Deng X, Wang J, et al. Modifiable risk factors associated with Moyamoya disease. *Stroke*; 2020. 51(8):2472-2479.
11. Xie A, Luo L, Ding Y, Li G. Ischemic and hemorrhagic moyamoya disease in adults: CT findings. *Int J Clin Exp Med*; 2015. 8(11):21351-7.
12. Gupta A, Tyagi A, Romo M, Amoroso KC, Sonia FNU. Moyamoya Disease: A Review of Current Literature. *Cureus*; 2020. 12(8): e10141.
13. Li J, Jin M, Sun X, Li J, Liu Y, Xi Y, et al. Imaging of Moyamoya Disease and Moyamoya Syndrome: Current Status. *J Comput Assist Tomogr*; 2019. 43(2):257-263.
14. Fujimura M, Tominaga T, Kuroda S, Takahashi JC, Endo H, Ogasawara K, et al. 2021 Japanese Guidelines for the Management of Moyamoya Disease: Guidelines from the Research Committee on Moyamoya Disease and Japan Stroke Society. *Neurol Med Chir (Tokyo)*; 2022. 62(4):165-170.
15. Takemoto K, Atagi K. Champagne bottle neck sign with moyamoya disease. *QJM*. 2022;115(5):314-315.
16. Pilgram-Pastor S, Chapot R, Kraemer M. The angiographic presentation of European Moyamoya angiopathy. *J Neurol*; 2022. 269: 997–1006.
17. Kleindorfer DO, Towfighi A, Chaturvedi S, et al. 2021 Guideline for the Prevention of Stroke in Patients with Stroke and Transient Ischemic Attack: A Guideline from the American Heart Association/American Stroke Association. *Stroke*; 2021. 52(7):e483-e484.
18. Pang CH, Cho WS, Kang HS, Kim JE. Benefits and risks of antiplatelet medication in hemodynamically stable adult moyamoya disease. *Sci Rep*; 2021. 11:19367
19. Hirano Y, Miyawaki S, Imai H, Hongo H, Ohara K, Dofuku S, Teranishi Y, Nakatomi H, Saito N. Association Between the Onset Pattern of Adult Moyamoya Disease and Risk Factors for Stroke. *Stroke*; 2020. 51(10):3124-3128.
20. Flach C, Muruet W, Wolfe CDA, Bhalla A, Douiri A. Risk and Secondary Prevention of Stroke Recurrence: A Population-Base Cohort Study. *Stroke*; 2020. 51(8):2435-2444.