



## RECURRENT BRAIN ABSCESS IN 40-YEARS-OLD FEMALE ASSOCIATED WITH VENTRICULAR SEPTAL DEFECT: A CASE REPORT

Azmi Farah Fairuzya<sup>1\*</sup>, Martha Oktavia Dewi Savitri<sup>1</sup>, Hanindia Riani Prabaningtyas<sup>1</sup>, Yasuhiro Watanabe<sup>2</sup>, Takenobu Murakami<sup>2</sup>, Yuki Tajiri<sup>2</sup>

\*Correspondence: [fairuzyazmi@gmail.com](mailto:fairuzyazmi@gmail.com)

<sup>1</sup>Department of Neurology, Faculty of Medicine, Universitas Sebelas Maret, Surakarta, Indonesia

<sup>2</sup>Department of Neurosurgery, Faculty of Medicine, Tottori University, Tottori, Japan

### Article History:

Received: January 16, 2024

Accepted: March 6, 2024

Published: January 1, 2025

### Cite this as:

Fairuzya AF, Savitri MOD, Prabaningtyas HR, Watanabe Y, Murakami M, Tajiri Y. Recurrent Brain Abscess in 40-Years-Old Female Associated with Ventricular Septal Defect: A Case Report. *Magna Neurologica*. 3(1) January 2025: 5-9. 10.20961/magnaneurologica.v2i2.1123

### ABSTRACT

**Background:** Ventricular septal defect (VSD) is one of the critical risk factors for brain abscess. The unsterile blood in uncontrolled cyanotic congenital heart disease cases will travel to the brain after escaping the filtration mechanism and cause brain abscess.

**Case:** A 40-year-old female presented with a two-week course of moderate headaches, worsening severely four days before admission. Neurological manifestations included attention deficits, dysarthria, right-sided hemiparesis, and proper facial palsy. Laboratory findings indicated leukocytosis and polycythemia. Echocardiography revealed VSD. Brain MRI with contrast suggested a single abscess lesion in the left occipital lobe. A histopathological examination confirmed the diagnosis. Antibiotics were administered during hospitalization, with outpatient treatment afterward. A one-month follow-up revealed new symptoms and a subsequent surgical excision.

**Discussion:** Brain abscess remains a challenging and life-threatening case despite advanced diagnostic techniques. Uncontrolled cyanotic heart disease might be an essential risk factor for brain abscess occurrence. Thorough diagnostic examinations must be conducted to establish the diagnosis. The optimal empirical-targeted antibiotic treatment is a cornerstone of management. After antibiotic therapy, a surgical approach must be considered in lesions with large-size or nonoptimal size reduction. It is essential to comprehensively manage brain abscesses and their etiology to reduce the recurrence rate.

**Conclusion:** Brain abscess associated with uncontrolled cyanotic congenital heart disease requires comprehensive treatment involving antibiotics and surgery. Addressing underlying causes and cost-effective follow-ups with clinical and monthly imaging assessments are essential.

**Keywords:** brain abscess, cyanotic heart disease, ventricular septal defect



This is an open access article distributed under the terms of the Creative Commons Attribution-4.0 International License

## Introduction

Brain abscess is an intraparenchymal infection characterized by a localized weakening area of the brain parenchyma in the early stage (cerebritis). Following an infection process, it develops into an encapsulated collection of pus, immune cells, and other materials.<sup>1,2</sup> The prevalence of brain abscess is approximately 0.3–1.3 per ten thousand people per

year.<sup>3</sup> In the Danish National Patient Registry, the incidence of brain abscess increased from 0.4 in 2007 to 0.8 per 100.000 adults in 2020.<sup>4</sup>

The source of infection, clinical presentation, and outcomes of brain abscess vary significantly across populations based on underlying comorbidities and predisposing conditions.<sup>5</sup> Cyanotic congenital heart disease (CHD) has been an important risk factor for brain abscess. The most common form was tetralogy

of Fallot (TOF), followed by ventricular septal defect (VSD) and transposition of great vessels.<sup>4</sup> Based on previous nationwide cohort studies, CHD caused a two-fold risk of CNS infection, such as brain abscess.<sup>6</sup> The incidence of brain abscess in patients with CHD is estimated at 2% over 13-year follow-up. Right-to-left shunting increased the risk of brain abscess by arterial bacteremia and hypoxic nidus for focal brain infection (due to hyperviscosity).<sup>7</sup>

We presented here a single case of a 40-year-old female with a brain abscess and untreated congenital VSD as the underlying cause. This case report highlights the importance of early detection and correction of cardiac defects to prevent serious complications.

## Case Report

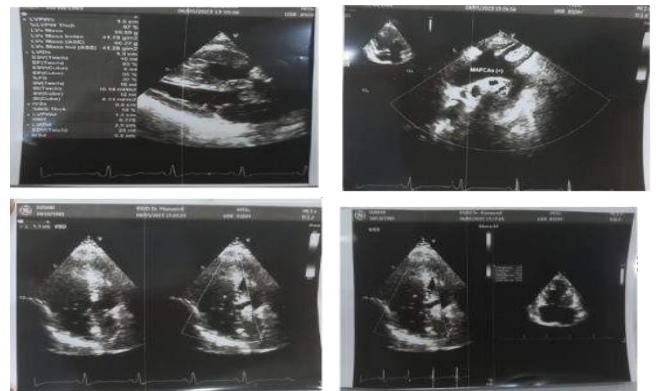
A 40-year-old female was admitted to our emergency room with two-week-course moderate headaches. Her headache worsened severely four days before admission, and she was unresponsive to over-the-counter analgesics. The patient felt nauseated and vomited while her headache worsened. The patient was confused and had difficulty communicating in the past four days. One week before admission, she complained of right-sided limb weakness and dysarthria. She frequently hits her surroundings due to her limited visual field. Histories of fever and malaise were obtained in the past two weeks. She had been diagnosed with some cardiac disease, but the details were unknown. No recent ear, nose, sinus, or dental infection history existed.

Her vital signs were stable, with blood pressure 110/60, heart rate 88 bpm, respiratory rate 18 breaths per minute, peripheral oxygen saturation 85%, and body temperature 37.80C. The clubbing finger was noted in the physical examination. The neurological examination showed that the patient was alert with Glasgow Coma Scale (GCS) E4V5M6, attention deficits, dysarthria, right-sided spastic hemiparesis, and proper facial palsy. She never experienced seizures. Early neuroimaging modality using non-enhanced brain CT showed a single mass in the left occipital lobe surrounded by perifocal edema.

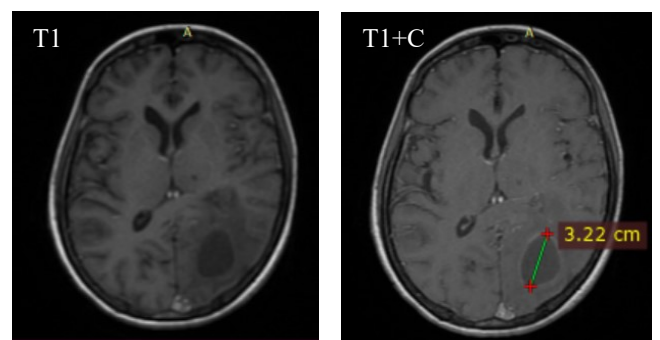
The patient was hospitalized, and further diagnostic workup was conducted. The laboratory findings indicated leukocytosis (WBC 17,800/ $\mu$ L) and polycythemia (Hemoglobin 20.4 g/dl, hematocrit 61%, erythrocyte 6.14 million/ $\mu$ L). Echocardiography reported VSD, severe pulmonary valve stenosis, and a good ejection fraction (EF) of 60% (Figure 1). Brain MRI with contrast enhancement shown in Figure 2 suggested a single lesion brain abscess in the left occipital lobe. The diameter of the abscess was about.

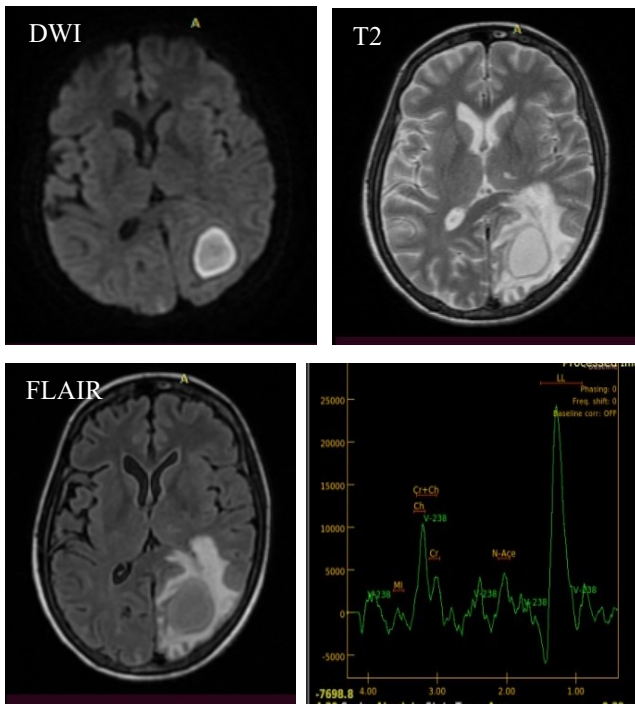
3.23 cm. MR spectroscopy showed the dominance of lipid lactate. Based on the imaging results, the patient was subsequently diagnosed with a brain abscess. Ceftriaxone (2 g every 12h) and metronidazole (500 mg every six h) were initially administered according to our standard practice. Comprehensive treatment was also done through consultation with the internal medicine and cardiology departments. After ten days of hospitalization, the patient was discharged with clinical improvement. In the outpatient setting, the patient was given oral cefixime (200 mg every 12h) and metronidazole (500 mg every six h).

During the one-month follow-up, the patient still complained of constant headaches and new-onset dizziness. Imaging evaluation using a contrast-enhanced brain CT scan shown in Figure 3 suggested a slight diameter reduction compared to a prior lesion in the left occipital lobe and an additional lesion in the left cerebellum (diameter 1.19 cm). We decided to consult the neurosurgery department for this reason. Surgical excision was conducted in addition to prolonged antibiotics. The histopathological examination confirmed brain abscess (Figure 4). The pus culture obtained from the surgical sample showed no growth. Blood culture indicated *Kocuria rosea*, which was a probable contaminant. After one week of hospitalization, the patient reported symptom relief and was discharged with continuous oral antibiotics.

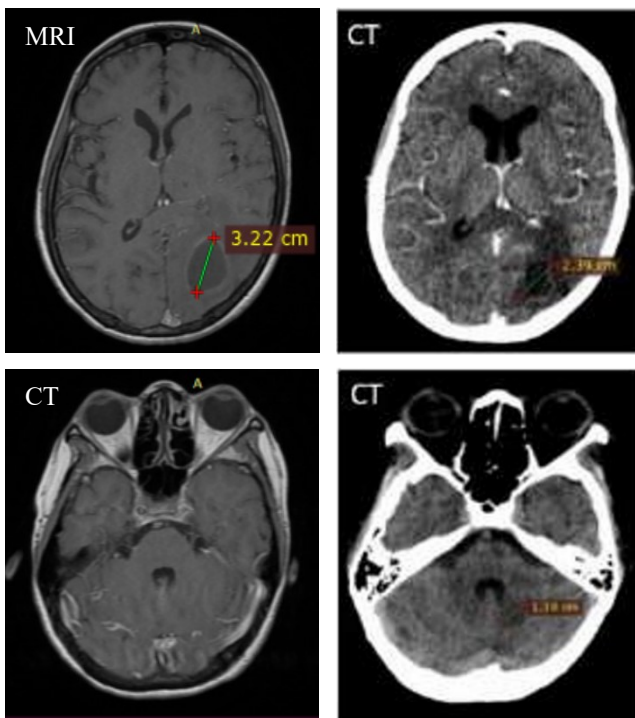


**Figure 1.** Echocardiography reported ventricular septal defect (VSD), severe Pulmonary Valve Stenosis, and good ejection fraction (EF) 60%

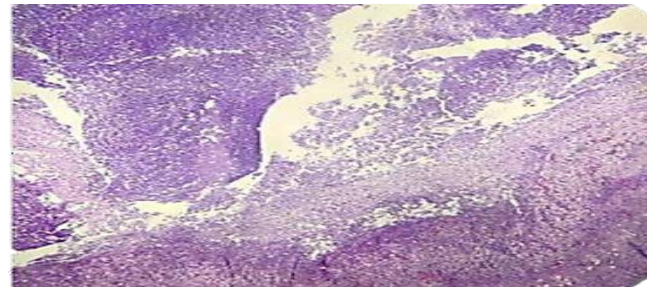




**Figure 2.** Brain MRI with contrast revealed the presence of a brain abscess located in the left occipital lobe, measuring approximately 3.23 cm in diameter. Additionally, MR Spectroscopy demonstrated a significant elevation of lipid-lactate levels, further supporting the diagnosis of a brain abscess



**Figure 3.** MRI images (left) from the initial examination and subsequent evaluation using a CT scan with contrast (right) revealed a slight reduction in the diameter of the previously identified lesion in the left occipital lobe. Additionally, a new lesion with a diameter of 1.19 cm was observed in the left cerebellum, indicating further progression of the condition.



**Figure 4.** Histological examination identified brain abscess with granulation tissue, extensive necrosis, and inflammatory infiltrates

## Discussion

Brain abscesses are ubiquitous central nervous system infections requiring thorough intervention. A brain abscess is a brain-focal infection with an encapsulated area of pus and central necrosis. The pus is formed from cerebritis, which is well vascularized. Brain abscess remains a challenging case despite advanced diagnostic techniques. It is a life-threatening condition with a risk of neurological deficits and long-term complications.<sup>3,9,8</sup> From a previous meta-analysis by Robertson et al. (2018), the overall global number of intracranial abscesses reached 1 million people per year, and Southeast Asia had the most significant incidence of 49 per 100,000.<sup>10</sup>

The hematogenous spread of brain abscesses to the intracranial compartment mainly originates from lung diseases, such as lung abscesses, bronchiectasis, empyema, and pneumonia.<sup>11</sup> Moreover, brain abscess might also occur in patients with uncorrected cyanotic CHD with a right-to-left shunt.<sup>12</sup> Tetralogy of Fallot (TOF), VSD, and transposition of great vessels become the most common cardiogenic risk factors of brain abscess.<sup>3</sup> Our patient was diagnosed with cyanotic VSD, confirmed by echocardiography. In uncontrolled cyanotic CHD, as recently presented, the right-to-left shunt causes bypass of the standard filtration mechanism by pulmonary capillaries, so venous blood with low oxygen concentration circulates within arterial blood. The bypass process results in bacteria escaping the lymphatic system and releasing the bacteria into circulation. The pathogens finally reached the brain. The low-oxygen environment allows pathogens to survive. In chronic hypoxemia, acidosis within the brain's grey-white matter interface eases bacteria growth.<sup>12,13</sup> Cyanotic CHD may lead to polycythemia and increase blood viscosity due to chronic hypoxemia. Ischemic conditions produce microinfarction areas suitable for creating a nidus of infection.<sup>14</sup> Our patient's laboratory results identified secondary polycythemia as a compensatory response to chronic hypoxia. This viscous blood also favors the pathogen to survive.

Clinical manifestations of brain abscess vary depending on its lesion site. The most frequent symptom is headache.<sup>3</sup> Brain abscess has a classical triad of headache, fever, and focal neurological deficit presented in about 20% of patients.<sup>9</sup> Those three were found in our patient. Our patient also complained of visual field deficits because the lesion was at the occipital lobe. Right-sided-spastic hemiparesis might be a false localizing sign commonly found in space-occupying lesions causing considerable vasogenic edema and herniation. From the previous hospital, a non-enhanced brain CT scan was done. A diagnosis of brain abscess usually begins with a brain CT or brain MRI. In this case, an early brain CT scan showed a round hypodense mass with a thin ring, suggesting late cerebritis. A brain MRI with contrast was conducted one week later and suggested an early encapsulated brain abscess with well-defined wall and rim enhancement. In the early capsule phase, the abscess is a well-defined mass with hyperintense cores on T2/FLAIR, and the rim is usually thin and smooth. DWI sequences are restricted strongly in necrotic core lesions.<sup>15</sup>

Histopathological analyses confirmed the diagnosis of brain abscess in our case. Pus and blood culture examinations were obtained on the same day. Pus culture from tissue samples showed no growth due to long-term antibiotic exposure. A blood culture examination revealed *K. rosea*. *K. rosea* are low-virulence, gram-positive bacteria found as normal skin flora and opportunistic pathogens. Its infections are rare in patients with brain abscesses, so we suggested that the bacteria are possible contaminants.<sup>16</sup> On the other hand, *Streptococcus* and *Haemophilus* spp are the most frequently isolated microbes in patients with cyanotic CHD; appropriate antimicrobial therapy should be started as early as possible.<sup>3</sup>

The optimal empirical and targeted antibiotic treatment is the cornerstone of managing brain abscesses. Our patient was firstly given a broad-spectrum empirical antibiotic for brain abscess, 2 grams of ceftriaxone every 12 hours, and 500 mg of metronidazole every 6 hours. European Society of Clinical Microbiology and Infectious Diseases strongly recommends 3rd-generation cephalosporin combined with metronidazole for empirically treating brain abscesses.<sup>17</sup> In our setting, we did not withhold the antibiotic regimen because surgery could not occur within 24 hours of radiological diagnosis. After five weeks of antibiotic treatment, 10 days intravenously, and the remaining days via oral, the patient complained of new onset dizziness and headache, indicating a suboptimal response to antibiotic therapy. A contrast-enhanced brain CT scan identified a slight diameter reduction compared to a prior lesion in the left occipital lobe and an additional lesion in the left

cerebellum. As mentioned in previous research, treatment failure cumulative incidence in brain abscess was higher in the non-surgical group (vs. early surgical intervention within 1 week).<sup>16</sup> At six weeks of onset, the patient was operated on, and the excision method was preferred. Neurosurgical aspiration or excision of brain abscess as soon as possible in all patients, whenever feasible, is strongly recommended. Neurosurgery is also pivotal in brain abscess management to control the source of infection.<sup>17</sup>

In our study, the patient had leukocytosis and polycythemia, which may increase the risk of brain abscess recurrence. Kiran et al. reported a recurrence in a 7-year-old patient previously treated at age 2. This patient developed polycythemia, which further results in tissue hypoxia and ischemia, creating a suitable environment for the growth of bacteria.<sup>19</sup> Udayakumaran et al. (2017) mentioned that unresolved congenital CHD might be a risk factor for brain abscess occurrence, persistence, and recurrence.<sup>20</sup> The recurrent brain abscess was primarily found in patients with higher hemoglobin and hematocrit levels. A previous study by Rens et al. (2021) suggested that the recurrence of brain abscesses might be due to untreated pulmonary arteriovenous malformation.<sup>21</sup> A survey by Nam et al. (2016) also mentioned prior studies discussing recurrent brain abscesses. Most studies found recurrence of brain abscess in patients with idiopathic arteriovenous malformation. This probable cause had not been further examined in our study.<sup>22</sup>

## Conclusion

Brain abscess is an intraparenchymal infection requiring comprehensive interventions. In our case, uncontrolled cyanotic CHD becomes a significant risk factor. Besides standard management with antibiotic and surgical approaches, thoroughly managing its etiology is also essential. Regarding cost-effectiveness, we conduct periodic follow-ups using clinical and monthly imaging examinations to evaluate the therapeutic success.

## Acknowledgment

Gratitude is extended to the Neurology Staff and residents of the Department of Neurology, Faculty of Medicine, Universitas Sebelas Maret Indonesia, and Tottori University Japan for their invaluable support in preparing this manuscript.

## References

1. Feraco P, Donner D, Gagliardo C, Leonardi I, Piccinini S, Del Poggio A, Franciosi R, Petralia B, &

- den Hauwe L. Cerebral abscesses imaging: A practical approach. *Journal of Population Therapeutics and Clinical Pharmacology*; 2020. 27(3): e14-e27. <https://doi.org/10.15586/jptcp.v27i3.6>.
2. Huang J, Wu H, Huang H, Wu W, Wu B, Wang L. Clinical characteristics and outcome of primary brain abscess: a retrospective analysis. *BMC Infectious Diseases*; 2021. 21:1245
  3. Brouwer MC, Tunkel AR, McKhann GM, van de Beek D. Brain Abscess. *N Engl J Med*; 2015. 371:447-456. DOI: 10.1056/NEJMra1301635
  4. Bodilsen J, et al., Risk factors for brain abscess: a nationwide, population-based, nested case-control study, *Clin. Infect. Dis*; 2020. 71(4):1040–1046.
  5. Campopli CC, O; Hor JC, Lahr BD, Wilson WR, Baddour LM, van Gompel JJ, Sohail MR. Predictors of Treatment Failure in Patients With Pyogenic Brain Abscess. *World Neurosurg*; 2022.16:100134. <https://doi.org/10.1016/j.wnsx.2022.100134>
  6. Bagge CN, Smit J, Madsen NL, Olsen M. Congenital Heart Disease and Risk for Central Nervous System: A Nationwide Cohort Study. *Pediatric Cardiology*; 2020. 41:869–876
  7. Gaeta SA, Ward C, Krasuski RA. Extra-cardiac manifestations of adult congenital heart disease. *Trends in Cardiovascular Medicine*; 2016. 26(7):627-636
  8. Chen K, Jiang P. Brain abscess associated with ventricular septal defect and Eisenmenger syndrome: A case report. *Int J Surg Case Rep*; 2021 Apr. 81:105799. doi: 10.1016/j.ijscr.2021.105799. Epub 2021 Mar 19. PMID: 33756163; PMCID: PMC8020423.
  9. Sonnevile R, Ruimy R, Benzonana N, Riffaud L, Carsin A, Tadié JM, Piau C, Revest M, Tattevin P; ESCMID Study Group for Infectious Diseases of the Brain (ESGIB). An update on bacterial brain abscess in immunocompetent patients. *Clin Microbiol Infect*; 2017. 23(9):614-620. doi: 10.1016/j.cmi.2017.05.004. Epub 2017 May 10. PMID: 28501669.
  10. Robertson FC, Lepard JR, Mekary RA, Davis MC, Yunusa I, Gormley WB, Park KB, et al. Epidemiology of central nervous system infectious diseases: a meta-analysis and systematic review with implications for neurosurgeons worldwide. *Journal of Neurosurgery*; 2018:1–20. doi:10.3171/2017.10.jns17359
  11. Bokhari MR, Mesfin FB. Brain Abscess. *StatPearls Publishing [Internet]*. 2022. <https://www.ncbi.nlm.nih.gov/books/NBK441841/>- Diakses pada Oktober 2023
  12. Obiorah S, Zitzmann J, Lane K, Toms S. Right frontal lobe intracranial brain abscess associated with a rare cardiac venous developmental anomaly: Implication of cardiac venous anomalies with a right-left shunt. *Interdisciplinary Neurosurgery*; 2020. 21: 100730. doi: 10.1016/j.inat.2020.100730
  13. Hall A, White MA, Gallo P. An intra-cerebral abscess in a patient with Eisenmenger syndrome: An unusual case. *Int J Surg Case Rep*; 2016. 20:138-41. doi: 10.1016/j.ijscr.2016.01. 025. Epub 2016 Jan 25. PMID: 26859871; PMCID: PMC4818319.
  14. Udayakumaran S, Onyia CU. Brain Abscess in Children. In: Alexiou, G., Prodromou, N. (eds) *Pediatric Neurosurgery for Clinicians*. 2022. Springer, Cham. [https://doi.org/10.1007/978-3-030- 80522-7\\_ 46](https://doi.org/10.1007/978-3-030- 80522-7_ 46)
  15. Osborn AG, Hedlund GL, Salzman KL. *Osborn's Brain Imaging, Pathology, and Anatomy*. 2018. Second Edition. Philadelphia: Elsevier
  16. Campioli CC, Almeida NEC, O'Horo JC, Wilson WR, Cano E, DeSimone DC. Diagnosis, management, and outcomes of brain abscess due to gram-negative versus gram-positive bacteria; 2022. 115: 189-194
  17. Bodilsen J, et al. European Society of Clinical Microbiology and Infectious Diseases guidelines on diagnosing and treating brain abscesses in children and adults. *Clinical Microbiology and Infection (Article in Press)*; 2023. ISSN 1198-743X, <https://doi.org/10.1016/j.cmi.2023.08.016>.
  18. Montoya JEM, Moran MAM, Ardila JAB, Henao PGC, Rodriguez EEM, Meza GAC. Brain abscess by *Kocuria rosea*: Case report and literature review. *Interdisciplinary Neurosurgery*; 2017: 59-61
  19. Kiran A 2nd, Taksande A, Chaudhary R. Recurrent Brain Abscess in a Child With Cyanotic Congenital Heart Disease. *Cureus*; 2022. 14(12):e32618. doi: 10.7759/cureus.32618. PMID: 36660522; PMCID: PMC9845802.
  20. Udayakumaran S, Onyia CU, Kumar RK. Forgotten? Not Yet. Cardiogenic Brain Abscess in Children: A Case Series-Based Review. *World Neurosurg*; 2017.107:124-129. doi: 10.1016/j.wneu.2017.07.144. Epub 2017 Aug 2. PMID: 28780403
  21. Rens J, Van Thielen T, Derweduwien A, Goedseels K, Hes R, de Jong L. Screening in cryptogenic brain abscess: Do not forget pulmonary arteriovenous malformations. *Surg Neurol Int*; 2021.12:188. doi: 10.25259/SNI\_51\_2021. PMID: 34084616; PMCID: PMC8168651.
  22. Nam TK, Park YS, Kwon JT. Brain Abscesses Associated with Asymptomatic Pulmonary Arteriovenous Fistulas. *J Korean Neurosurg Soc*; 2017. 60(1):118-124. doi: 10.3340/jkns.2015.0707.023. Epub 2016 Dec 29. PMID: 28061502; PMCID: PMC5223758.