



OLFACTORY NEUROBLASTOMA WITH INTRACRANIAL EXTENSION

Andry Nurwahyu Putra Romadhoni^{1*}, Iqbal Imanuddin¹, Teddy Tejomukti¹, Yasuhiro Watanabe², Takenobu Murakami², Yuki Tajiri²

*Correspondence andry_putra_medical@yahoo.com

¹Department of Neurology, Faculty of Medicine, Universitas Sebelas Maret, Surakarta, Central Java, Indonesia

²Neurosurgery Department, Faculty of Medicine, Tottori University, Tottori, Japan

Article History:

Received: February 13, 2024

Accepted: March 20, 2024

Published: July 1, 2024

Cite this as:

Imanuddin I, Romadhoni ANP, Tejomukti T, Watanabe Y, Murakami T, Tajiri Y. Olfactory Neuroblastoma with Intracranial Extension. *Magna Neurologica*. 2(2) July 2024: 70-76. 10.20961/magnaneurologica.v2i2.1164

ABSTRACT

Background: Olfactory Neuroblastoma (ONB), so called esthesioneuroblastoma, is a rare malignant tumor of the sinonasal tract. ONB represents 6.3% of all sinonasal tract malignancies, with a prevalence of 0.4 cases per million population. These tumors are slow-growing and there may be intracranial extension of the tumor. Nasal obstruction, anosmia, recurrent epistaxis and pain are typical early manifestations. Imaging studies are essential in determining tumor extension and surgical planning of ONB. Endonasal biopsy is required to confirm the diagnosis of ONB. The case provides a basis for discussion of ONB and highlights the possibility of extension of this tumor.

Case: A 45-year-old male presented with a generalized clonic seizure, conjugate eye deviation, and pre-seizure headache. Post-seizure, the patient was unconscious and incontinent, later appearing conscious but confused. The patient had a history of seizures at home and in the ER, along with occasional headaches over the past year. The patient described nasal congestion, decreased smell, and recurrent nosebleeds, having undergone ethmoidectomy in 2020 for papilloma.

Discussion: The patient experienced symptoms of seizures, headache, and nasal disturbances. Olfactory neuroblastoma (ONB) tumor was detected after comprehensive examination. Treatment involves multimodal therapy, including surgery, chemotherapy, and radiotherapy, with prognosis depending on tumor stage and grade.

Conclusion: Early diagnosis of ONB is necessary to prevent further tumor progression. Intracranial extension of the ONB should be carefully investigated. Imaging as well as histopathological and immunohistochemical examinations are very helpful in identifying the location, metastasis and degree of malignancy of the tumor.

Keywords: esthesioneuroblastoma; intracranial extension; olfactory neuroblastoma



This is an open access article distributed under the terms of the Creative Commons Attribution-4.0 International License

Introduction

Olfactory Neuroblastoma (ONB), so called esthesioneuroblastoma, is a rare malignant tumor originating from sensory cells of the olfactory epithelium.^{1,2} ONB represents 6.3% of all sinonasal tract malignancies, with a prevalence of 0.4 cases per million population.¹ There is a bimodal age distribution with a peak in young adult patients around the 2nd decade and another peak in the 5th to 6th decade with no gender or racial predilection.^{1,4,5} The etiology is unclear, but there are several associated risk factors,

such as smoking, exposure to chemicals and hazardous particles, wood dust, wheat, nickel, cadmium dust, glue, formaldehyde, and other solvents.¹

The most common symptoms are nasal obstruction, anosmia, recurrent epistaxis, and pain.^{1,4} Because most clinical manifestations are nonspecific, ONB is often missed at an early stage and not diagnosed until it reaches an advanced stage. They are slow-growing tumors and may also have intracranial extension.¹ They begin as a mass in the superior olfactory recess that initially affects the anterior ethmoid airfluid and media

unilaterally. As it grows, it tends to damage the surrounding bone and may extend to all directions.¹ Clinical examination and nasal endoscopy reveal a soft tissue mass in the superior olfactory recess. The most frequent site of metastasis is the cervical lymph nodes (10-33% of patients), while other rare sites of malignancy are the lungs, brain and bone.^{1,9} Imaging studies are essential in determining tumor extension and surgical planning of ONB. CT scan and MRI are the first choice in assessing ONB. CT scans are particularly useful for assessing bone damage due to tumor expansion. One of the most characteristic findings is a "dumbbell-shaped" mass that crosses the cribriform plate. MRI is a good choice to evaluate intraorbital and intracranial extension. Kadish et al. proposed a classification based on the extension from the nasal cavity using CT scan and MRI.^{1,3}

Hyams classification is an important factor in determining prognosis, with overall survival rates of 56% for low grade (I and II) and 25% for high grade (III and IV).^{3,4} Optimal therapy depends on tumor extension and histological grade, with treatment options being multimodality therapy in combination with surgery followed by radiation therapy with or without chemotherapy.^{4,6} Here, we reported a case of ONB presenting with intracranial extension and a history of ethmoidectomy with a diagnosis of papilloma.

Case Report

Mr. WA, 45 years old, had seizure and came to the emergency room. During seizure, the patient's whole body twitched and his eyes glared upwards for <2 minutes, before the seizure the patient complained of headache, during the seizure the patient was unconscious, incontinent and after the seizure the patient was conscious but seemed confused. The patient had once seizure at home and once in the emergency room. The patient first experienced a seizure in December 2022 with a same form of seizure. At that time the patient seized up to 4x causing the patient to be taken to Rumah sakit umum daerah Dr. Moewardi (RSDM) and took anti-seizure drugs until now. The drug that the patient routinely takes is levetiracetam.

The patient also complained that since one year he had occasional headaches. The headache is intermittent, aggravated at night and when the patient coughs. As time goes by, the headache becomes more frequent. The family also complained that since September 2022 the patient became difficult to communicate with. The patient became forgetful, agitated and confused. The patient responds for a long time when spoken to. Sometimes the patient understands when invited to communicate, sometimes he cannot be invited to

communicate at all. The patient also complains of nasal congestion and decreased olfactory perception. These complaints have been felt since 2020. Then the patient saw an ENT doctor and was said to have polyps. The patient underwent ethmoidectomy surgery in November 2020 with the result of pathology anatomy (PA) inverted papilloma. Complaints of nasal congestion had improved but currently feel again. The patient used to have frequent nosebleeds, but now they are less frequent. There is no visual impairment or double vision. There is no weakness of half of the limbs, no seizures, no nausea or vomiting. Currently there is no history of fever. There is no complaint of defecation and urination. Due to current complaints, the patient was referred to a neurologist. Then the patient was examined CT Scan and MRI, it was said that the patient had a tumor in the frontal brain area. In October 2022 the patient underwent surgery to remove the tumor by a Neurosurgeon with the results of PA meningioma transitional type WHO grade I. Currently the complaints of headache and communication disorders have improved, but there are still residual symptoms.

In the neurological status examination, there was an attentional disorder with the Karnofsky Performance Scale obtaining a score of 70. In the laboratory results on 5 May 2023 there was a leukocytosis of 24,000 / LU and an increase in current blood sugar (190 mg/dL), HbA1c (6.8%), fasting blood sugar (145 mg/dL) and 2-hour glucose postprandial (236 mg/dL). From the results of multi-slice computed tomography (MSCT) brain examination without contrast on 19 September 2022 there was a solid lesion with indistinct boundaries with irregular edges filling the right maxillary sinus, bilateral ethmoidal sinuses, bilateral frontal sinuses, bilateral sphenoidal sinuses, osteomeatal complex and bilateral cavum nasi infiltrating bilateral concha nasalis media et inferior, causing destruction of the posterior superior wall et media of the right maxillary sinus, bilateral posterior superior inferior lateral wall et media of bilateral ethmoidal sinuses, superior anterior wall et media of right sphenoidal sinus, posterior wall et superior of left sphenoidal sinus lamina cribriformis and septum nasi, extending to the right frontotemporal region accompanied by surrounding vasogenic edema leading to a picture of sinonasal mass. There is also multiple lymphadenopathy in the bilateral colli, sublingula and bilateral submandibula (Figure 1).

The preoperative contrast-enhanced brain MRI examination on 22 September 2022 showed a supratentorial extraaxial lesion originating from the olfactory bulb that extended to the bilateral ethmoidal sinuses, right-sided choana and right cavum nasi, bilateral sphenoidal sinuses, sinus cavernosus, extending to the right frontal lobe intracranial, and urging the midline to the left by 1.2 cm leading to a

picture of Olfactory Neuroblastoma. The lesion gets arterial feeding from the branching of the right internal carotid artery and appears bilateral frontal and right maxillary sinusitis (Figure 2) (Figure 3) (Figure 4). The MRI brain contrast exam on September 22, 2022, showed a supratentorial extraaxial lesion with clear borders and irregular edges in the olfactory groove. It had a bleeding component, CSF cleft sign, perifocal edema, partially restricted diffusion area, blooming artifact, and strong contrast enhancement with a dural tail extending to the bilateral nasal cavity, ethmoid sinus, maxillary sinus, osteomeatal complex, sphenoidalis sinus, frontalis sinus, cavernosus sinus, right nasopharynx, bilateral concha nasalis media and inferior, eroding the nasal septum, pressing the right orbital cavity, medial rectus oculi muscle, optic chiasm, eroding the lamina cribrosa, and extending to the right frontal lobe, indicating a residual mass (olfactory groove meningioma) (Figure 5) (Figure 6).

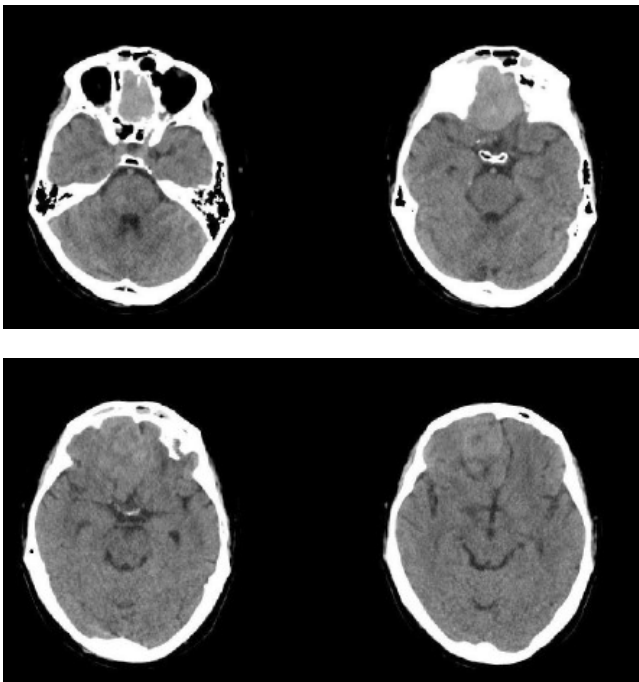


Figure 1. Brain MSCT without contrast

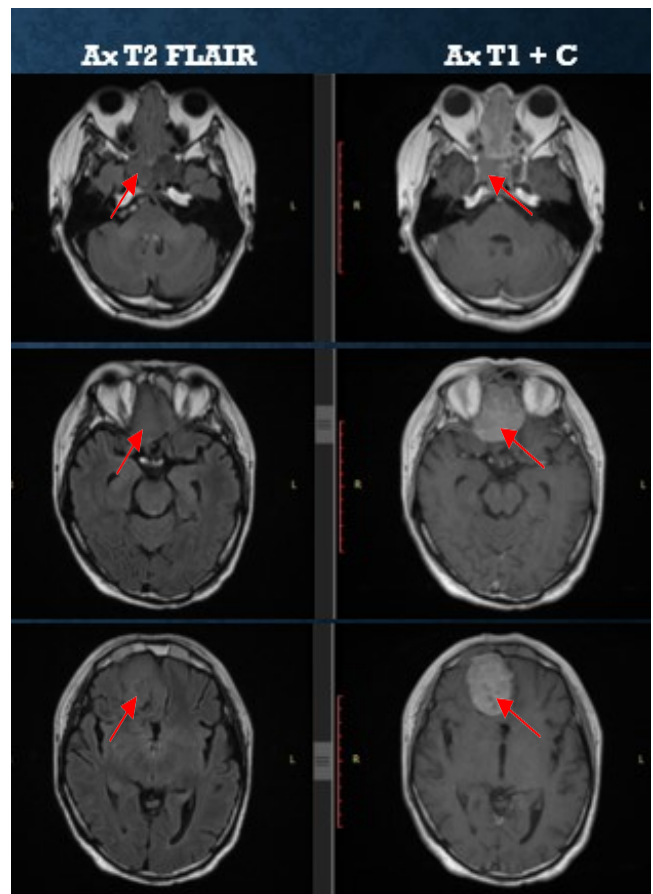
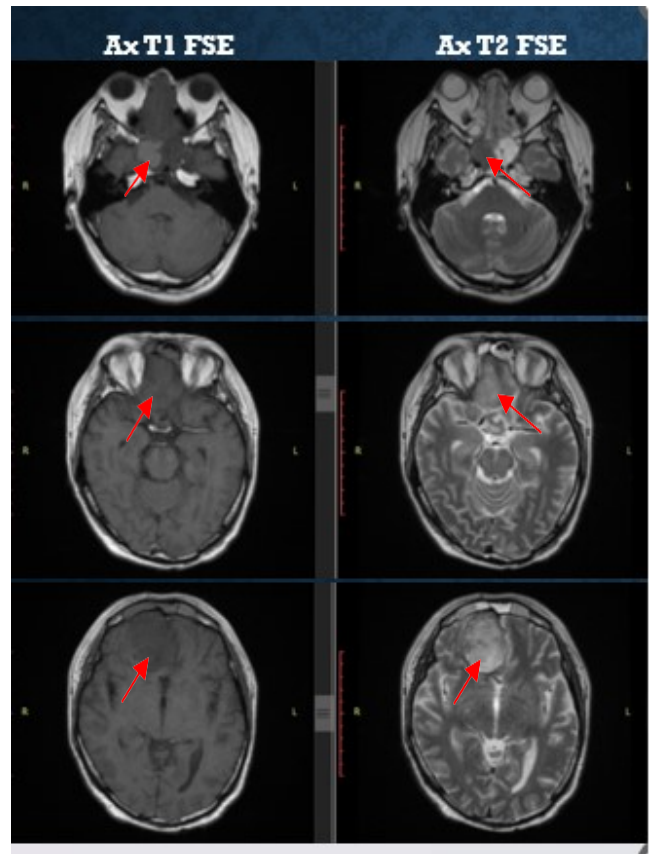


Figure 2. Preoperative axial brain MRI sequence T1, T2, T1 Contrast, T2 Flair

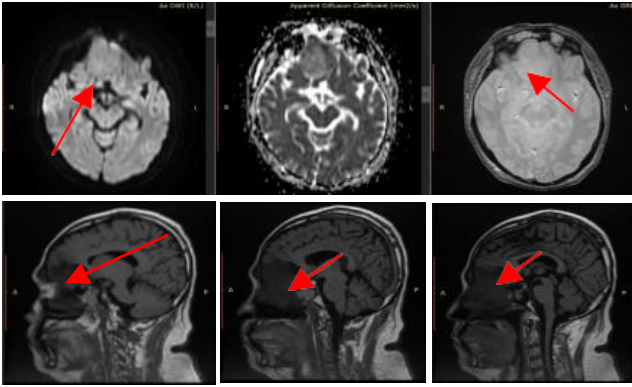


Figure 3. Preoperative axial and sagittal brain MRI sequence with contrast on September 22, 2022

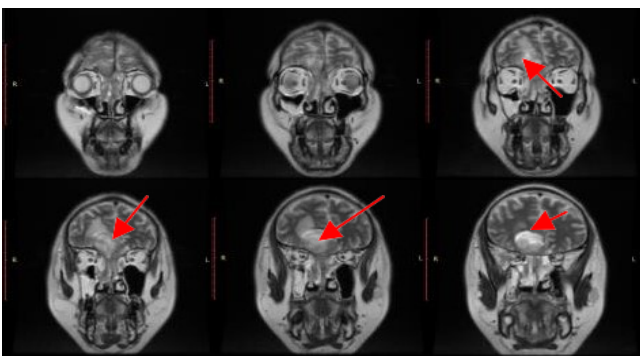


Figure 4. Preoperative coronal brain MRI sequence with contrast on September 22nd, 2022

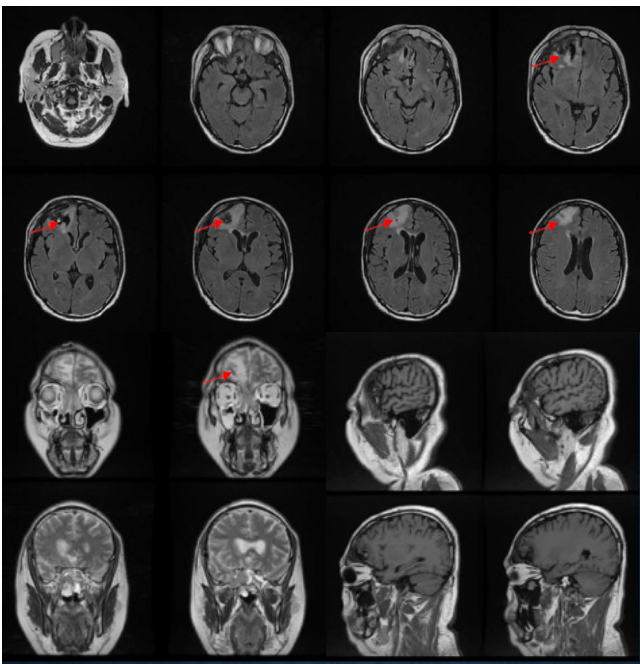


Figure 5. Postoperative axial, coronal, and sagittal brain MRI sequence with contrast on December 22nd, 2022

In the results of anatomical histopathological examination on 16 November 2020 preparations from the ethmoidal sinus showed pieces of sinus mucosa tissue coated with pseudo-layered epithelium with a polyp structure, a deep inverted image with a puffy myxoid structure, many capillaries and a mixture of lymphocytes and monocytes. With the conclusion of polyps with a picture of inverted papilloma (Figure 7). The results of histopathological anatomy of tissue of frontal origin on 10 October 2022 showed tumor nests in the form of tufts and a picture of "whorls". Atypical nucleus cells, spindle / oval, Mitosis is difficult to obtain with the conclusion of WHO grade I transitional type meningioma (Figure 8). The results of anatomical histopathology which was conducted on 25 December 2022, with tissue originating from the frontal region concluded transitional meningioma. As well as from the ethmoid sinus tissue obtained small round blue cell tumor, differential diagnosis: 1). Primitive neuroectodermal tumor (PNET). 2). Neuroblastoma. 3). Non-hodgkin lymphoma (NHL). The results of histopathological anatomy of ethmoidal sinus tissue preparations and polyps on 5 May 2023 resulted in a diagnosis of Ethmoidal Sinus Tissue (RS.2003495) with synaptophysin (positive diffuse in tumor cells), CD-99 (negative on tumor cells), CD-45 (negative on tumor cells): Based on the histopathological picture and immunohistochemistry (IHC) examination results, the tumor is suitable for Neuroblastoma.

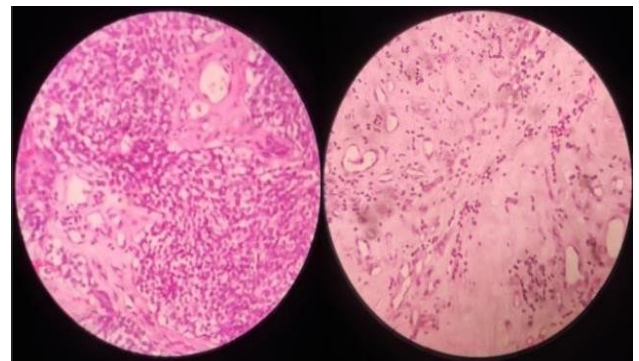


Figure 6. Histopathological anatomy of ethmoidal sinus preparations on November 16th, 2020

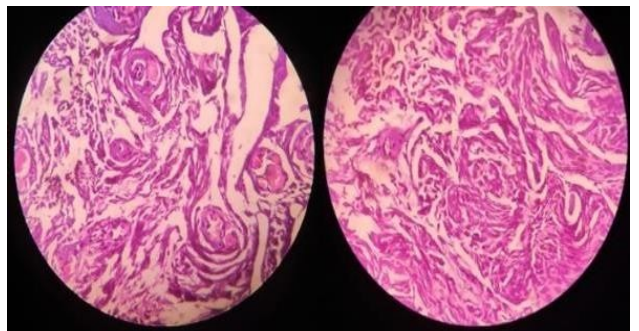


Figure 7. Histopathologic anatomy of frontal origin tissue October 10th, 2022

For pharmacologic medication, the patient was given intravenous fluid drops with ringer lactate 20 drops every minute, paracetamol infusion 1gr/12 hours, ranitidine injection 50 mg / 12 hours, mecobalamin injection 500 mcg / 12 hours, diazepam injection 10mg (pro re nata) seizures, loading injection dexamethasone 10 mg. Continued injection of dexamethasone 5 mg/8 hours taper off, levetiracetam 2x500mg and planned to undergo radiation therapy.

Discussion

In this case the patient came to the emergency room of RSDM with complaints of seizures, headache. In addition, the patient also had a history of complaints of nasal congestion, decreased smell and recurrent epistaxis. This is in accordance with existing theory. The most common symptoms found are nasal obstruction, anosmia, recurrent epistaxis, and pain.^{1,4} In advanced stages, symptoms associated with local expansion beyond the nose and paranasal sinuses will manifest, such as epiphora, diplopia, proptosis, and loss of visual acuity. Patients may present with symptoms of intracranial involvement, such as frontal lobe symptoms and seizures.^{4,10} These tumors grow slowly and there may also be intracranial extension of the tumor.¹ They begin as a mass in the superior olfactory recess that initially affects the anterior ethmoid airfluid and media unilaterally. As it grows, it tends to damage the surrounding bone and may extend in all directions. As most clinical manifestations are non-specific, ONBs are often missed in the early stages and not diagnosed until they reach an advanced stage.^{1,9}

The patient has a history of ethmoidectomy in 2020 with the results of PA inverted papilloma. And a history of excisional craniotomy in October 2022 with a PA result of WHO grade I transitional type meningioma. Clinical examination and nasal endoscopy revealed a soft tissue mass in the superior olfactory recess. The tumor usually, presents as a unilateral reddish-gray soft polypoid mass, with intact mucosa in the medial part of the middle turbinate. The most frequent site of metastasis is the cervical lymph nodes (10-33% of patients), while other rare sites of malignancy include the lungs, brain and bone.^{1,11}

Based on clinical, radiological, and histological findings, olfactory neuroblastoma was diagnosed. Immunohistochemistry with a panel of markers confirmed the diagnosis. Imaging studies are essential in determining tumor extension and surgical planning of ONB. CT scan and MRI are the first choice in assessing ONB. CT scan is very useful in assessing bone destruction due to tumor expansion, although it

cannot differentiate ONB from other tumors arising in the same region. One of the most characteristic findings is a "dumbbell-shaped" mass that crosses the cribriform plate. MRI is a good choice to evaluate intraorbital and intracranial extension with signal characteristics that include: T1: heterogeneous intermediate signal, T2: heterogeneous intermediate signal. T1 C+ (Gd): variable enhancement (usually moderate to intense). If there is intracranial extension, there is often a peritumoural cyst between the area and the brain.^{1,3}

A biopsy is required to confirm the diagnosis of ONB.^{7,12} ONB can be difficult to differentiate from other tumors, such as sinonasal undifferentiated carcinoma, primitive neuroectodermal tumor (PNET), rhabdomyosarcoma, lymphoma, and malignant melanoma on tumor morphology alone.^{7,12,13} Accurate diagnosis requires additional testing with immunohistochemical staining demonstrating positive staining for neuroendocrine markers (chromogranin, CD56, synaptophysin, and neuron-specific enolase (NSE)) and S-100 positive sustentacular cells lining the periphery of the tumor lobules.^{7,14} Negative markers include CD99, CD45RB, p63, and FL11. Proliferation marker studies reveal a variable Ki-67 proliferation index (2-50%), and BCL2 expression increases with tumor grade.^{8,15}

Histologically, ONBs consist of small round blue cells. These cells have round to oval-shaped nuclei, with scanty cytoplasm and well-demarcated chromatin. They also have a layer of malignant cells arranged in lobules through vascular fibrous septa, true neural rosettes (Flexner-Wintersteiner type) and pseudorosettes (Homer Wright type).^{1,4,16} Classification of ONB stage is important in choosing the most appropriate treatment and determining prognosis. Kadish et al. proposed a classification based on CT scans and MRI.^{1,3} This system divides tumors into three groups: group A - tumors confined to the nasal cavity; group B - tumors involving the nasal cavity and paranasal sinuses; group C - tumors extending beyond the nasal cavity and paranasal sinuses. Miorita et al. modified the system with the addition of group D for patients with regional (neck lymph nodes) or distant metastases.¹

Hyams classifies ONB into four other classes. ONB is dichotomously divided into low grade (Hyams' I-II) and high grade (Hyams' III-IV). However, recent large studies have shown that the division into low-grade (Hyams' I-III) and high-grade (Hyams' IV) cases shows better clinical correlation. High-grade ONB often presents with leptomeningeal metastasis, whereas low-grade ONB shows local-regional recurrence. Grade I tumors have a lobular architecture with prominent neurofibrillary matrix and small homogeneous cells

without mitotic activity. This grade often shows pseudorosettes (Homer-Wright rosettes). Grade II tumors usually show less prominent matrix and more cellular atypia with mitoses. Grade III tumors are more atypical with increased mitosis and necrosis and true neural rosettes (Flexner-Wintersteiner). Grade IV tumors are the least differentiated and difficult to diagnose as there is often loss of lobular architecture. Hyams classification is an important factor in determining prognosis, with an overall survival rate of 56% for low grade (I and II) and 25% for high grade (III and IV).^{3,4,17}

Optimal treatment depends on tumor extension and histological grade, with treatment options being multimodality therapy with a combination of surgery followed by radiation therapy with or without chemotherapy.^{4,6,18} The traditional surgical approach for ONB is an anterior craniofacial resection, which involves a bifrontal craniotomy combined with a transfacial lateral rhinotomy. This surgical procedure is performed, if required, by a team of neurosurgeons and ENT experts. In the last two decades, endoscopic approaches have gained popularity, producing comparable oncologic outcomes, limiting surgical morbidity and length of hospital stay.^{4,19} Chemotherapy and radiation have been used in the management of esthesioneuroblastoma in an effort to decrease surgical morbidity.²⁰ At Harvard, non-surgical approaches including neoadjuvant chemotherapy using cisplatin and etoposide followed by proton therapy showed excellent results. Mishima et al. achieved complete responses in 8 out of 12 patients with an aggressive multi-agent chemotherapy schedule. Turano et al. reported a case successfully treated using the same regimen, alternating Cisplatin Etoposide with Doxorubicin, Ifosfamide and Vincristine.⁶

Conclusion

ONB is a rare case of malignant tumor. Even benign tumor like nasal cavity papilloma or intracranial meningioma, tumor extension in and out of the brain should be carefully investigated. The results of MSCT scan and MRI radiological examination as well as histopathological examination and immunohistochemistry are very helpful in identifying the location, metastasis, and degree of malignancy of the tumor. Surgical therapy accompanied by radiation therapy and chemotherapy shows good result.

References

- Rusu B, Lupoi D, Dragomir M, Badea C. Olfactory neuroblastoma: Up-to-date review and our experience. *Romanian Journal of Rhinology*. 2023 Jul 1;13(51):94-102.
- Dumont RA, Palma Diaz MF, Hsu W, Sepahdari AR. Olfactory Neuroblastoma: Re-Evaluating the Paradigm of Intracranial Extension and Cyst Formation. *Diagnostics*. 2022 Mar 1;12(3):614.
- Czapiewski P, Kunc M, Haybaeck J. Genetic and molecular alterations in olfactory neuroblastoma: implications for pathogenesis, prognosis and treatment. *Oncotarget*. 2016 Aug 8;7(32):52584.
- Caballero RN, Morlana AG. Olfactory Neuroblastoma: Everything Radiologists Should Know. *Rev. Argent. Radiol*. 2020;84(1):17-31.
- Fortuno KM, Igot MO. An olfactory neuroblastoma with intracranial extension treated with chemotherapy and radiotherapy: A case report. *Philippine Journal of Health Research and Development*. 2021 Sep 28;25(3):94-104.
- Thomas S, Balasubramaniam D, Hiran K, Dinesh M, Pavithran K. Esthesioneuroblastoma with intracranial extension: A non-surgical approach. *Asian Journal of Neurosurgery*. 2016 Sep;11(03):313-.
- Maurer R, Henry A, Maurer T, Staity G, Williams N, Goyal N. Heavily calcified esthesioneuroblastoma in a 72-year-old. *Cureus*. 2019; 11: e4298.
- Limaïem F, Das JM. Esthesioneuroblastoma. *StatPearls [Internet]*. 2022 Jan.
- Abdelmeguid AS. Olfactory neuroblastoma. *Current oncology reports*. 2018 Jan;20:1-7.
- Veyrat, M. et al. (2020) 'Olfactory Neuroblastoma', in *Anterior Skull Base Tumors*. Basel, Switzerland: S. Karger AG, pp. 154–167.
- Topcagic J, Feldman R, Ghazalpour A, Swensen J, Gatalica Z, Vranic S. Comprehensive molecular profiling of advanced/metastatic olfactory neuroblastomas. *PLoS One*. 2018 Jan 11;13(1):e0191
- Meyer C, Hamersley ER, Manosalva RE, Torske K, McIntyre N, Mitchell A. Olfactory neuroblastoma with divergent differentiation: an unusual histologic finding in a rare tumor. *Head and Neck Pathology*. 2017 Dec;11:531-6.
- Lopez F, Agaimy A, Franchi A, Suárez C, Vander Poorten V, Mäkitie AA, Homma A, Eisbruch A, Olsen KD, Saba NF, Nuyts S. Update on olfactory neuroblastoma. *Virchows Archiv*. 2024 Feb 22:1-9.
- Rooper LM, Bishop JA, Faquin WC, Foss RD, Gallia GL, Jo VY, Lewis Jr JS, Nishino M, Stelow EB, Thompson LD, Wenig BM. Sinonasal tumors with neuroepithelial differentiation (olfactory carcinoma): delineation of their pathologic and clinical features with insights into their relationship to olfactory neuroblastoma and sinonasal carcinoma. *The American Journal of Surgical Pathology*. 2022 Aug 1;46(8):1025-35.

15. Czapiewski P, Kunc M, Haybaeck J. Genetic and molecular alterations in olfactory neuroblastoma: implications for pathogenesis, prognosis and treatment. *Oncotarget*. 2016 Aug 8;7(32):52584.
16. Okano K, Ishida M, Sandoh K, Ito H, Fujisawa T, Iwai H, Tsuta K. Review of the cytological features of olfactory neuroblastoma: A retrospective single-center study. *Diagnostic Cytopathology*. 2021 Aug;49(8):E301-6.
17. Choby G, Geltzeiler M, Almeida JP, Champagne PO, Chan E, Ciporen J, Chaskes MB, Fernandez-Miranda J, Gardner P, Hwang P, Ji KS. Multicenter survival analysis and application of an olfactory neuroblastoma staging modification incorporating Hyams grade. *JAMA Otolaryngology–Head & Neck Surgery*. 2023 Sep 1;149(9):837-44.
18. Abdelmeguid AS, Bell D, Roberts D, Ferrarotto R, Phan J, Su SY, Kupferman M, Raza S, DeMonte F, Hanna E. Long-Term Outcomes of Olfactory Neuroblastoma: MD Anderson Cancer Center Experience and Review of the Literature. *The Laryngoscope*. 2022 Feb;132(2):290-7.
19. Kim N, Lee CG, Kim EH, Kim CH, Keum KC, Lee KS, Chang JH, Suh CO. Patterns of failures after surgical resection in olfactory neuroblastoma. *Journal of neuro-oncology*. 2019 Jan 30;141:459-66.
20. Su SY, Bell D, Ferrarotto R, Phan J, Roberts D, Kupferman ME, Frank SJ, Fuller CD, Gunn GB, Kies MS, Glisson BS. Outcomes for olfactory neuroblastoma treated with induction chemotherapy. *Head & Neck*. 2017 Aug;39(8):1671-9.