



VITAMIN D DEFICIENCY IN RELAPSING ANTI-NMDAR ENCEPHALITIS PRESENTING WITH ACUTE COGNITIVE IMPAIRMENT: A CASE REPORT

Audiza Luthffia*, Cempaka Thursina Srie Setyaningrum, Amelia Nur Vidyanti, Desin Pambudi Sejahtera, Sekar Satiti

*Correspondence: audiza.luthffia@gmail.com

Department of Neurology, Faculty of Medicine, Universitas Gadjah Mada, Yogyakarta, Indonesia

Article History:

Received: July 23, 2024

Accepted: October 16, 2024

Published: January 1, 2025

Cite this as:

Luthffia A, Setyaningrum CTS, Vidyanti AN, Sejahtera DP, Satiti S. Vitamin D Deficiency in Relapsing Anti-Nmdar Encephalitis Presenting with Acute Cognitive Impairment: A Case Report. *Magna Neurologica*. 3(1) January 2025: 33-38. 10.20961/magnaneurologica.v3i1.1740

ABSTRACT

Background: Anti-N-methyl-D-aspartate Receptor (NMDAR) encephalitis is an autoimmune disease characterized by neuropsychiatric symptoms caused by autoantibodies against NMDAR. It is a treatable disease, but approximately 12-25% of patients experience relapse. Vitamin D has several immunomodulatory effects, and its deficiency is associated with systemic and neurologic autoimmune diseases.

Case: A 21-year-old woman presenting with acute cognitive impairment, followed by status epilepticus that occurred during hospitalization. Two years ago, she was diagnosed with anti-NMDAR encephalitis and wholly recovered after immunotherapy. During relapse, Magnetic resonance imaging (MRI) shows chronic lacunar infarct on the right basal ganglia, and electroencephalography (EEG) shows diffuse slowing; both results were identical to findings from the first event. Laboratory testing during relapse indicates vitamin D deficiency, which was expected before relapse onset. The symptoms improved following intravenous methylprednisolone, plasma exchange, vitamin D supplementation, and symptomatic treatment.

Discussion: Inadequate immunotherapy has been suggested as a significant risk factor for relapse, while other determinants have yet to be well recognized. Vitamin D inhibits the proliferation of B cells, an essential immunomodulator in anti-NMDAR encephalitis. A previous study revealed that vitamin D levels were reduced in anti-NMDAR encephalitis patients, which is also thought to influence response to therapy. On the other hand, vitamin D also influences neurotransmitter activities and synaptic formation involved in cognitive and memory functioning.

Conclusion: Anti-NMDAR encephalitis is a treatable autoimmune disease but still has the possibility of relapse. Vitamin D deficiency may be related to relapse of anti-NMDAR encephalitis. Routine screening for vitamin D deficiency can be considered in relapsed patients or during maintenance therapy.

Keywords: Anti-NMDAR encephalitis, autoimmune encephalitis, relapse, vitamin D



This is an open access article distributed under the terms of the Creative Commons Attribution - 4.0 International License

Introduction

Anti-N-methyl-D-aspartate Receptor (NMDAR) encephalitis is a rare autoimmune disease characterized by rapid onset neuropsychiatric symptoms associated with the presence of autoantibodies against the GluN1 sub-unit of NMDAR in the cerebrospinal fluid (CSF).¹ It is the most common

autoimmune encephalitis, with an estimated incidence of 1.5 per million yearly population.² Epidemiological studies show that anti-NMDAR encephalitis predominantly affects females at a young age (children and young adults).³

The treatment approach to anti-NMDAR encephalitis is early initiation of immunotherapies,

including high-dose steroids, intravenous immunoglobulin (IVIG), and plasma exchange (PLEX) given sequentially or concurrently.⁴ Following timely diagnosis and adequate treatment, up to 80% of patients achieved a good prognosis after 2 years of follow-up. Nevertheless, relapse occurs in 10-20% of patients. Many factors are thought to affect prognosis, but the scientific evidence needs to be more detailed, as well as studies addressing the cause of relapse.⁵

Vitamin D has several immunomodulatory properties, as vitamin D receptors (VDR) are found in many immune cells, such as lymphocytes, macrophages, and neutrophils. Vitamin D deficiency has been linked to the incidence and severity of various autoimmune diseases such as Multiple Sclerosis (MS), Systemic Lupus Erythematosus (SLE), and Rheumatoid Arthritis (RA).^{6,7} The effect of vitamin D in anti-NMDAR encephalitis is not well-established, especially in its relapse. Studies reporting cases of anti-NMDAR encephalitis relapse with vitamin D deficiency are rare. In this study, we report a case of relapsing anti-NMDAR encephalitis presenting with acute cognitive impairment 2 years following the first onset, who appeared to have vitamin D deficiency.

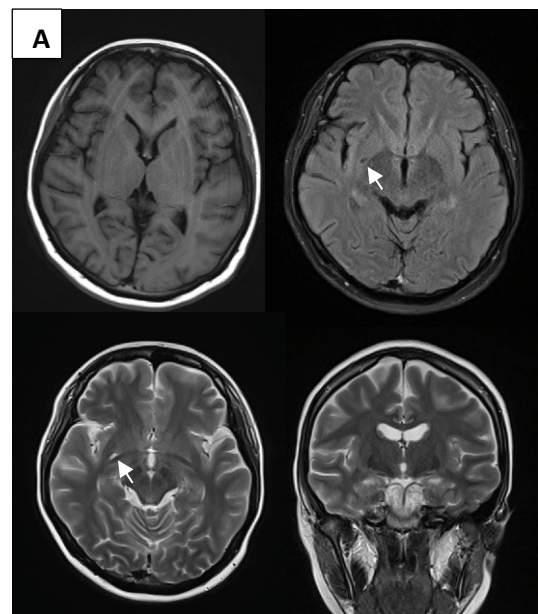
Case Report

A 20-year-old female with a history of anti-NMDAR encephalitis was admitted to our hospital with initial symptoms of acute cognitive impairment. She complained of recent memory loss, such as forgetfulness of recent information and activities and difficulty in performing calculation tasks since 5 days before admission. The patient is still able to carry out daily activities independently. Upon admission, overall general condition was good; cognitive examination using Mini-Mental State Examination (MMSE) and Montreal Cognitive Assessment- Indonesian version (Moca-Ina) shows a deficit in attention and delayed recall domain, with a total score of 26 and 27 for each test, respectively. She took 86 seconds in Trail Making Test A (TMT-A) and could not finish Trail Making Test B.

Laboratory tests were unremarkable, except for a low vitamin D-25-OH level of 9.03 ng/ml. Brain Magnetic Resonance Imaging (MRI) showed a pathologic lesion in the right basal ganglia, with a hypointense signal on T1 and FLAIR, hyperintense on T2, and non-restricted DWI. Electroencephalogram (EEG) showed asymmetric theta slowing in the right hemisphere. The MRI and EEG findings were similar to the result from the first attack (Figure 1). CSF analysis and examination for anti-NMDAR antibodies were not performed during this episode. Herpes simplex virus (HSV) testing was not performed due to insufficient examination kits.

High dose IV Methylprednisolone (250 mg per 6 hours) was given for 5 days, alongside IV Citalopram 500 mg per 12 hours, Memantine 5 mg once daily, vitamin D supplementation of 5000 IU daily while continuing valproic acid and azathioprine as her routine medication. After 9 days of hospitalization, she then developed focal onset general tonic-clonic seizure, which constitute status epilepticus. Following the seizure, she appeared agitated and disoriented. She was admitted to intensive care for close monitoring and treatment of continuous low-dose IV midazolam to prevent recurrent seizures as in the first attack. The seizure did not recur, and her cognitive function was improved following three cycles of plasma exchange and other symptomatic treatments.

Two years prior, she had a history of subacute onset of aggressive behavior, mutism, visual hallucinations, uncontrolled body movements, and status epilepticus followed by recurrent seizures. The condition was diagnosed as anti-NMDAR encephalitis from positive CSF anti-NMDAR antibody at 2 weeks following symptoms onset. She was treated with immunotherapies of high-dose steroids and three cycles of plasma exchange without any complications. She underwent treatment in the intensive care unit for 3 weeks but then recovered completely without any sequelae and was fully functional before developing the second attack. During that period, she was still doing a regular checkup and taking Azathioprine 50 mg once daily as maintenance immunotherapy and valproic acid 250 mg twice daily for seizure control. She was screened for vitamin D level and was normal 4 months before the onset of the second attack.



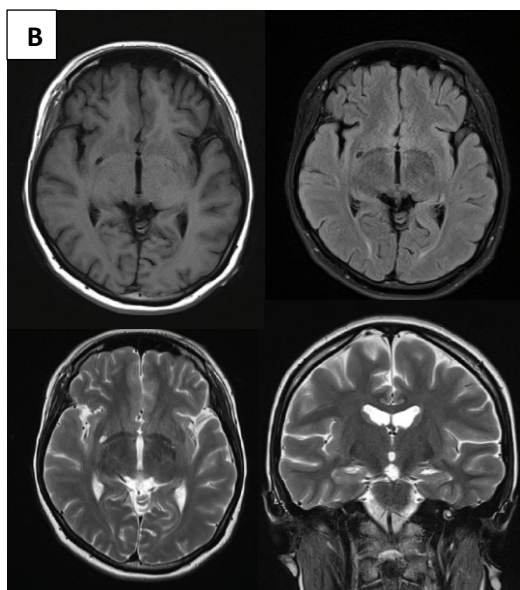


Figure 1. Brain MRI showing pathologic lesion in right basal ganglia, (A) Relapse episode, (B) First attack episode

Discussion

Diagnostic criteria for definite anti-NMDAR encephalitis require at least one of six major symptom groups with positive anti-NMDAR antibody testing on CSF. In the setting where CSF anti-NMDAR antibody cannot be examined, diagnosis of probable anti-NMDAR encephalitis can be made if at least four significant symptom groups are accompanied by supporting laboratory study.³ The patient's clinical presentation and the result of supporting examination on the first attack suit the diagnosis of definite anti-NMDAR encephalitis (Table 1).

Clinical relapsing autoimmune encephalitis is a return of previously resolved symptoms or new or acute worsening neuropsychiatric symptoms, seizures, or other neurologic symptoms after at least 1 month of clinical stability.⁸ Previous cohort studies showed that relapse occurs an average of 8 months following the first attack (range 3-54 months). Compared with the first onset, relapses are less severe and have considerably fewer symptoms or even monosymptomatic.⁹ Although this patient only had mild cognitive impairment as the only symptom, we still diagnosed her as relapsing anti-NMDAR encephalitis and administered high dose IV methylprednisolone upon admission because it suits the definition, time frame, and characteristics of relapse. There were fewer symptoms at relapse (cognitive dysfunction and seizure) compared to the onset (behavioral changes, movement disorder, mutism, seizure). The identical results of MRI and EEG between those two episodes may also indicate the same disease course. In addition, EEG findings are almost always abnormal (90-100%)

in anti-NMDAR encephalitis. Frequently presents generalized or focal slowing rather than epileptogenic activities.¹⁰

Table 1. Diagnostic Criteria for Anti-NMDAR Encephalitis

Diagnosis	Criteria
Probable	<ul style="list-style-type: none"> • Rapid onset (<3 months) of at least four of the six significant symptoms groups <ol style="list-style-type: none"> 1) Abnormal (psychiatric) behavior or cognitive dysfunction; 2) Speech dysfunction (pressured speech, verbal reduction, mutism); 3) Seizure; 4) Movement disorder, dyskinesias, or rigidity/abnormal postures; 5) Decreased level of consciousness; 6) Autonomic dysfunction or central hypoventilation • And at least one of the laboratory studies <ol style="list-style-type: none"> 1) Abnormal EEG (focal or diffuse slowing, disorganized activity, epileptic activity, or extreme delta brush); 2) CSF analysis of pleocytosis or oligoclonal band • Or three of the above groups of symptoms and identification of systemic teratoma • Exclusion of recent history of herpes simplex virus encephalitis or Japanese B encephalitis
Definite	<ul style="list-style-type: none"> • One or more of the six significant symptom groups and IgG GluN1 (anti-NMDAR) antibodies (should include CSF sample; if only serum is available, another confirmatory test should be included, such as cell-based assay and liver neurons or tissue immunohistochemistry) • Exclusion of recent history of herpes simplex virus encephalitis or Japanese B encephalitis

After a timely diagnosis, early administration of adequate immunotherapies is very crucial. It serves as a main prognostic factor, improving outcomes and reducing the risk of relapses.¹¹ It is a treatable disease, and a good outcome is achieved in patients using first-line immunotherapies alone. First-line immunotherapies include high-dose steroids, IVIG,

and plasma exchange, which can be administered in combination. Second-line immunotherapy, such as rituximab or cyclophosphamide, may be given to patients unresponsive to first-line immunotherapy.¹ The recommended steroid is methylprednisolone 1 gram daily for 3-5 days.¹² This patient received adequate immunotherapy, including high-dose steroids and three complete cycles of plasma exchange during both the first and second attacks, ensuring thorough management of the condition.

After treatment of acute onset, long-term maintenance immunotherapy should be considered as a preventive measure for relapse. Studies regarding the role and recommendation of maintenance immunotherapy are scarce. Azathioprine and Mycophenolate Mofetil are the most commonly used oral immunotherapies in autoimmune neurological diseases such as myasthenia gravis and neuromyelitis optic. These drugs may also be used following acute treatment of autoimmune encephalitis, as in this patient who was taking Azathioprine maintenance therapy. The appropriate treatment duration is still unknown.¹²

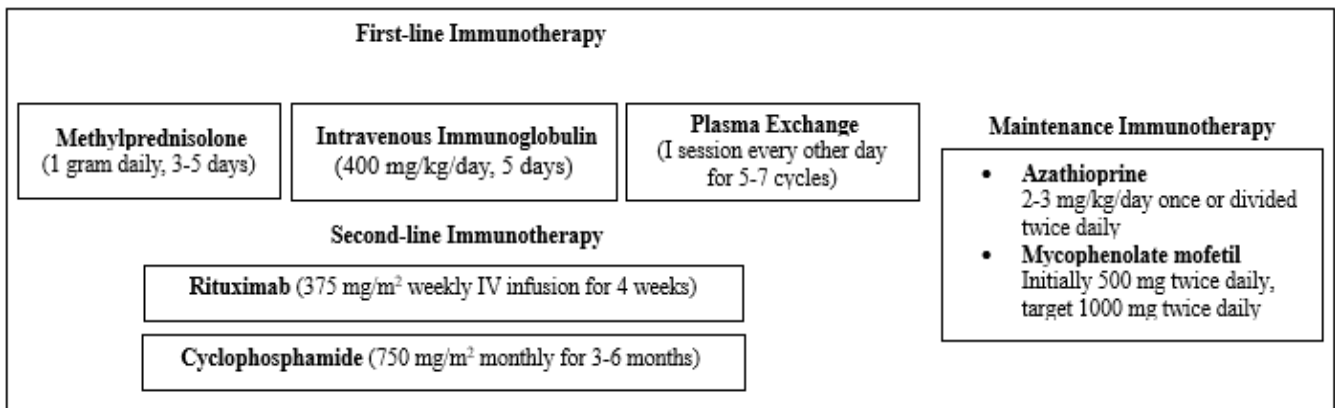


Figure 2. Treatment of anti-NMDAR encephalitis

According to a previous study, relapse was significantly higher in individuals with the manifestation of focal CNS deficit (HR: 3.150, 95% CI: 1.278-7.763; $p = 0.013$), MRI lesion in the frontal lobe or brainstem, and ≥ 3 MRI lesions at first disease event. Patients with delayed or insufficient immunotherapy during the first episode were also more likely to relapse. In contrast, receiving three or more different immunotherapies at the first event is a protective factor for relapse.^{9,13,14} During the first event, the reported patient had no profound focal CNS deficit; the MRI showed only a single lesion in basal ganglia and had received acute treatment of high-dose steroid and plasma exchange that was continued with maintenance immunotherapy. Thus, the risk and triggering factors of the patient's relapse in this case were still questionable.

During the relapse episode, the patient was found to have a deficiency in vitamin D despite having normal vitamin D levels recorded during routine check-ups conducted 4 months before the relapse. In the absence of other known risk factors, without any abnormalities detected in laboratory tests, and with supporting examinations showing no evidence of worsening or further damage compared to the initial episode, our analysis suggests that vitamin D deficiency may have played a significant role as a potential triggering factor for the relapse.

Vitamin D deficiency has also been associated with other systemic and neurologic autoimmune diseases. Vitamin D has anti-inflammatory and immunomodulatory functions that may explain its relationship with several autoimmune diseases. Vitamin D exerts its anti-inflammatory and immunomodulatory function through vitamin D receptors expressed on cells of the innate immune system, such as macrophages and dendritic cells, as well as cells of the adaptive immune system, including CD4 T cells, CD8 T cells, B cells, and natural killer lymphocytes. First, it suppresses in vitro T cell proliferation, IL2 and interferon secretion by CD4 T cells, and the cytotoxicity of CD8 T cells. Second, it inhibits the production of various cytokines by T-helper. Third, it inhibits activated B cell proliferation and induces their apoptosis. In the setting of vitamin D deficiency, those processes will be affected, causing vitamin D deficiency as an environmental trigger that increases the occurrence of autoimmune diseases.^{17,18}

A case-control study of 30 patients with anti-NMDAR encephalitis (vs. healthy control) showed that serum vitamin D-25-OH levels were reduced in patients with anti-NMDAR encephalitis. The low vitamin D levels were associated with female sex, younger age, and worse disease prognosis. Vitamin D levels may also contribute to successful treatment in

anti-NMDAR encephalitis, in which higher vitamin D levels were observed in patients with favorable responses to therapy compared with those with limited responses (Figure 2). Analysis of inflammatory infiltrates in brain samples from anti-NMDAR encephalitis patients demonstrated prominent B cell cuffing around brain vessels accompanied by plasma cells. Immune cells, mainly B cells, are essential effectors and regulators of inflammation and autoimmunity in anti-NMDAR encephalitis. Hence, it is plausible that low serum vitamin D may be a risk factor for developing anti-NMDAR encephalitis, as it might affect immune cells, especially B cells.^{17,19}

Vitamin D also impacts synaptic functions, cognition, and behavior. Vitamin D receptors (VDR) are found in the cortex and hippocampus, two crucial brain areas for several cognitive functions. An animal study showed that vitamin D deficiency might alter neurotransmitter signaling, increasing impulsive behavior and impairing social interaction, learning, and memory. In contrast, vitamin D supplementation promotes synapse development, regulates synaptic protein, improves learning ability, and increases sociability.²⁰ Most studies mainly focused on cognitive deficits in an older population, especially in dementia, and the evidence of a relationship between vitamin D and autoimmune-related cognitive impairment is still limited.^{21,22} We could not conclude whether vitamin D deficiency influences the development of cognitive deficits present in these patients.

Generally, low serum vitamin D levels may be influenced by vitamin D intake, ultraviolet (UV) exposure, or rarely a vitamin D receptors (VDR) polymorphism. We did not specifically identify the cause of vitamin D deficiency in this patient. Still, the patient was a student who spent most of her time indoors, and the relapse episode occurred in late February, which is still the rainy season in Indonesia; both factors may lead to low UV exposure. Previous studies have also linked the pattern of multiple sclerosis occurrence in various seasons.⁷

Even though the association between vitamin D deficiency and autoimmune diseases is well established, the recommendation for vitamin D supplementation for such cases is still debatable.²³ There was still limited study regarding routine vitamin D supplementation in autoimmune encephalitis; the current evidence supports vitamin D supplementation in the setting of prolonged corticosteroid treatment to prevent toxicity.²⁴

Conclusion

Anti-NMDAR encephalitis is a treatable autoimmune disease but still has the possibility of

relapse. Timely and adequate treatment favors a good prognosis and may prevent relapse. However, relapse may still occur in patients who have received adequate therapy. Factors associated with relapse have yet to be clearly understood. Vitamin D deficiency may become one of the relapsing factors due to its effect on the immune system. Routine vitamin D screening should be considered in patients on maintenance therapy following acute episodes of anti-NMDAR encephalitis, and vitamin D supplementation may be given, if indicated, as a preventive measure for relapse.

References

1. Huang Q, Xie Y, Hu Z, Tang X. Anti-N-methyl-D-aspartate receptor encephalitis: A review of pathogenic mechanisms, treatment, prognosis. Vol. 1727, Brain Research. Elsevier B.V.; 2020.
2. Datta A, Pandit A, Biswas S, Biswas A, Roy B, Gangopadhyay G. Spectrum of anti-NMDA receptor antibody encephalitis: Clinical profile, management and outcomes. Ann Indian Acad Neurol. 2021 May 1;24(3):383–9.
3. Graus F, Titulaer MJ, Balu R, Benseler S, Bien CG, Cellucci T, et al. A clinical approach to the diagnosis of autoimmune encephalitis. Vol. 15, The Lancet Neurology. Lancet Publishing Group; 2016. p. 391–404.
4. Nguyen L, Wang C. Anti-NMDA Receptor Autoimmune Encephalitis: Diagnosis and Management Strategies. Vol. 16, International Journal of General Medicine. Dove Medical Press Ltd; 2023. p. 7–21.
5. Wang H, Xiao Z. Current Progress on Assessing the Prognosis for Anti-N-Methyl-D-Aspartate Receptor (NMDAR) Encephalitis. Vol. 2020, BioMed Research International. Hindawi Limited; 2020.
6. Athanassiou L, Mavragani CP, Koutsilieris M. The Immunomodulatory Properties of Vitamin D. Mediterr J Rheumatol. 2022;33(1):7–13.
7. Dankers W, Colin EM, van Hamburg JP, Lubberts E. Vitamin D in autoimmunity: Molecular mechanisms and therapeutic potential. Vol. 7, Frontiers in Immunology. Frontiers Media S.A.; 2017.
8. Yakir MJ, Yang JH. Treatment Approaches in Pediatric Relapsing Autoimmune Encephalitis. Current Treatment Options in Neurology. Springer; 2024.
9. Feng J, Yang M, Cui D, Huang Z, Ji T, Lian Y. Recurrence of Anti-N-Methyl-D-Aspartate Receptor Encephalitis: A Cohort Study in Central China. Front Neurol. 2022 Mar 7;13.
10. Gillinder L, Warren N, Hartel G, Dionisio S, O’Gorman C. EEG findings in NMDA encephalitis – A

- systematic review. Vol. 65, Seizure. W.B. Saunders Ltd; 2019. p. 20–4.
11. Nosadini M, Thomas T, Eyre M, Anlar B, Armangue T, Benseler SM, et al. International Consensus Recommendations for the Treatment of Pediatric NMDAR Antibody Encephalitis. *Neurol Neuroimmunol Neuroinflamm.* 2021 Sep 22;8(5).
 12. Shin YW, Lee ST, Park K Il, Jung KH, Jung KY, Lee SK, et al. Treatment strategies for autoimmune encephalitis. Vol. 11, *Therapeutic Advances in Neurological Disorders.* SAGE Publications Ltd; 2018.
 13. Gong X, Chen C, Liu X, Lin J, Li A, Guo K, et al. Long-term Functional Outcomes and Relapse of Anti-NMDA Receptor Encephalitis: A Cohort Study in Western China. *Neurol Neuroimmunol Neuroinflamm.* 2021 Mar 15;8(2).
 14. Nosadini M, Granata T, Matricardi S, Freri E, Ragona F, Papetti L, et al. Relapse risk factors in anti-N-methyl-D-aspartate receptor encephalitis. *Dev Med Child Neurol.* 2019 Sep 1;61(9):1101–7.
 15. Hassanalilou T, Khalili L, Ghavamzadeh S, Shokri A, Payahoo L, Bishak YK. Role of vitamin D deficiency in systemic lupus erythematosus incidence and aggravation. Vol. 9, *Autoimmunity Highlights.* Springer-Verlag Italia s.r.l.; 2018.
 16. Min JH, Waters P, Vincent A, Cho HJ, Joo BE, Woo SY, et al. Low Levels of Vitamin D in Neuromyelitis optica spectrum disorder: Association with disease disability. *PLoS One.* 2015 Sep 1;9(9).
 17. Shu Y, Su Q, Liao S, Lu T, Li R, Sun X, et al. Low serum vitamin D levels and anti-N-methyl-D-aspartate receptor encephalitis: A case-control study. *Neurochem Int.* 2017 Jan 1;102:89–94.
 18. Plantone D, Primiano G, Manco C, Locci S, Servidei S, De Stefano N. Vitamin D in Neurological Diseases. Vol. 24, *International Journal of Molecular Sciences.* MDPI; 2023.
 19. Simma N, Bose T, Kahlfuß S, Mankiewicz J, Lowinus T, Lühder F, et al. NMDA-receptor antagonists block B-cell function but foster IL-10 production in BCR/CD40-activated B cells. *Cell Communication and Signaling.* 2015;12(1).
 20. Ye X, Zhou Q, Ren P, Xiang W, Xiao L. The Synaptic and Circuit Functions of Vitamin D in Neurodevelopment Disorders. Vol. 19, *Neuropsychiatric Disease and Treatment.* Dove Medical Press Ltd; 2023. p. 1515–30.
 21. Lu Y, Li J, Hu T, Huang G. Serum 25-hydroxy vitamin D level is associated with cognitive impairment in people 65 years and older. *Ann Palliat Med.* 2021 Jul 1;10(7):7479–85.
 22. Gáll Z, Székely O. Role of vitamin D in cognitive dysfunction: New molecular concepts and discrepancies between animal and human findings. Vol. 13, *Nutrients.* MDPI; 2021.
 23. Bivona G, Gambino CM, Sasso B Lo, Scazzone C, Giglio RV, Agnello L, et al. Serum Vitamin D as a Biomarker in Autoimmune, Psychiatric and Neurodegenerative Diseases. Vol. 12, *Diagnostics.* Multidisciplinary Digital Publishing Institute (MDPI); 2022.
 24. Abboud H, Probasco JC, Irani S, Ances B, Benavides DR, Bradshaw M, et al. Autoimmune encephalitis: Proposed recommendations for symptomatic and long-term management. Vol. 92, *Journal of Neurology, Neurosurgery and Psychiatry.* BMJ Publishing Group; 2021. p. 897–907.