



## A RARE CASE OF ANOMIC APHASIA AND GERSTMANN SYNDROME INDUCED BY HEMORRHAGIC STROKE

Daniel Mahendrakrisna<sup>1\*</sup>, Bagus Ngurah Mahasena Putera Awatara<sup>2</sup>, Gede Suputra<sup>2</sup>, Ni Wayan Nurlina Ekasari<sup>2</sup>, Dian Kusumastuti Anggraeni Putri<sup>2</sup>, Anak Agung Ayu Putri Laksmidewi<sup>1</sup>

\*Correspondence: [danielkrisna24@gmail.com](mailto:danielkrisna24@gmail.com)

<sup>1</sup>Department of Neurology, Prof. DR. I.G.N.G. Ngoerah Hospital, Denpasar, Indonesia

<sup>2</sup>Department of Neurology, Mangusada Hospital, Badung, Indonesia

### Article History:

Received: February 28, 2025

Accepted: May 9, 2025

Published: July 1, 2025

### Cite this as:

Mahendrakrisna D, Awatara BNMP, Suputra G, Ekasari NWN, Putri DKA, Laksmidewi AAAP. A Rare Case of Anomic Aphasia and Gerstmann Syndrome Induced by Hemorrhagic Stroke. *Magna Neurologica*. 3(2) July 2025: 71-75.  
10.20961/magnaneurologica.v3i2.2262

### ABSTRACT

**Background:** Aphasia is a language disorder caused by brain damage, such as a stroke. Anomic aphasia, a rare subtype, impairs the ability to name objects or people while preserving fluency and comprehension. It is often associated with Gerstmann syndrome, which is characterized by acalculia, finger agnosia, left-right disorientation, and semantic aphasia. This report presents a case of a 61-year-old male with anomic aphasia and Gerstmann syndrome following a hemorrhagic stroke.

**Case:** A 61-year-old male patient presented with sudden difficulty recalling the names of family members and objects. Imaging revealed an intracerebral hemorrhage in the left parietotemporooccipital lobe. The patient also exhibited left-right disorientation and finger agnosia, indicative of Gerstmann syndrome. The Aphasia Test for Rehabilitation Information Diagnosis (TADIR) confirmed the diagnosis of anomic aphasia. Although conservative treatment led to partial improvement, naming difficulties and associated deficits persisted.

**Discussion:** Anomic aphasia primarily involves difficulties with naming, typically resulting from lesions in the dominant hemisphere, particularly the temporal and parietal lobes. Its coexistence with Gerstmann syndrome underscores the complexity of overlapping neurological deficits. The TADIR test was crucial in diagnosing and managing the patient's condition.

**Conclusion:** This case highlights the importance of a thorough evaluation in aphasia cases, especially when rare syndromes like Gerstmann syndrome are involved. Early and accurate diagnosis enables targeted interventions that can improve patient outcomes.

**Keywords:** anomia, aphasia, Gerstmann's syndrome, intracranial hemorrhages, stroke



This is an open access article distributed under the terms of the Creative Commons Attribution - 4.0 International License

## Introduction

Aphasia is a language disorder that results from brain damage, such as a stroke, and often harms sufferers. One of the rare aphasias is anomic aphasia. Anomic aphasia is a language disorder in which sufferers find it difficult to find words for an object or person. This condition affects various aspects of communication, including speaking, understanding, reading, and writing, and can lead to substantial limitations in a person's daily life. For individuals with aphasia, effectively communicating is essential for maintaining social relationships, achieving independence, and

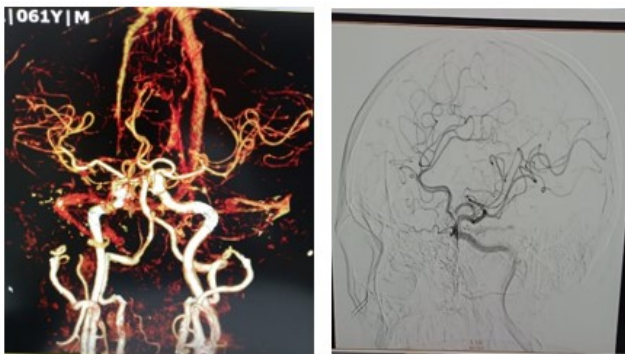
participating in daily activities. The impact of aphasia on quality of life is profound, as it can contribute to frustration, social isolation, and even depression.<sup>1-3</sup>

Anomic aphasia is often associated with Gerstmann's rare and unique syndrome.<sup>2</sup> Gerstmann syndrome includes acalculia or counting disorders, finger agnosia or the patient's inability to recognize one's or other people's fingers, left-right disorientation, and semantic aphasia, which rarely occur entirely together.<sup>4,5</sup> We report a rare case of a 61-year-old man with anomic aphasia and Gerstmann syndrome secondary to hemorrhagic stroke.

## Case Report

A 61-year-old male patient, right-handed, came with his family, complaining that he suddenly could not remember the names of family members about 30 minutes before going to the hospital. The patient feels these complaints when he is finished in the bathroom. The patient can remember their name, but suddenly cannot remember the names of other family members. The patient also cannot remember the names of objects that are familiar to them. The patient can speak fluently and understands what other people are saying. Previously, the patient had felt a headache, like a throbbing pain throughout the head, mild to moderate intensity, which improved with medication.

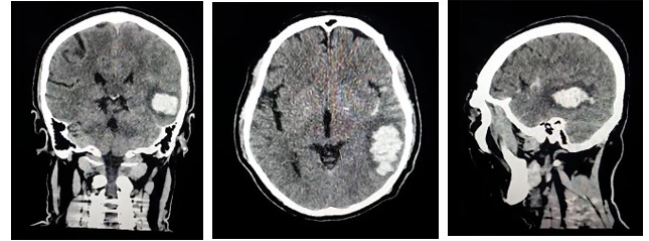
Three days before the complaint appeared, the patient had shown symptoms of forgetfulness, which, according to the patient's wife, occurred suddenly. At that time, the patient was shopping. When at the shopping place, the patient suddenly went blank and forgot what to shop for; after that, the patient could remember again. The patient has a history of indirect carotid-cavernous fistula (CCF) and Cervical Nucleus Pulposus Herniation. The patient has no history of diabetes mellitus (DM), Hypertension, or anticoagulant or antiplatelet consumption. The patient is a highly educated person who does not smoke or drink alcohol. The patient has no history of trauma (Figure 1).



**Figure 1.** Brain Computed Tomography Angiography (CTA) before onset (left) and Digital Subtraction Angiography (DSA) before onset (right) show no macrovascular lesion, excluding CCF

The patient was assessed in the emergency room, where it was observed that he continued to experience difficulty recalling the names of objects and the names of his family members. However, he was still able to remember and state his name. His vital signs were within normal limits. During the clinical examination, the patient appeared alert and responsive. He was noted to have symptoms consistent with anomic aphasia. No signs of cranial nerve paresis were detected, no motor weakness was detected, and pathological reflexes were absent. A non-contrast Computed Tomography (CT) scan of the brain was subsequently performed, which revealed an intracerebral haemorrhage located in the left

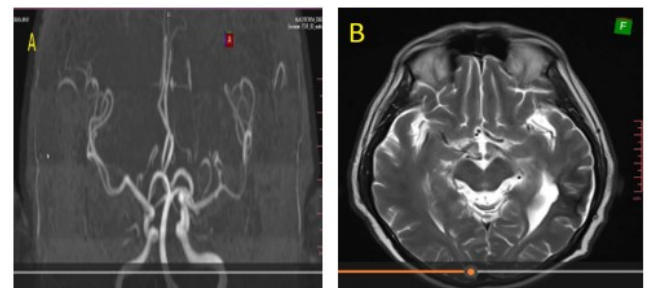
parietotemporooccipital lobe. Additional investigations, including a chest X-ray, showed no abnormalities in the heart or lungs. Electrocardiography (ECG) findings indicated sinus bradycardia, while laboratory test results fell within normal parameters. Following these evaluations, the patient was admitted to the hospital for further management and received conservative treatment.



**Figure 2.** A non-contrast Brain CT scan revealed an intracerebral hemorrhage located in the left parietotemporooccipital lobe. The findings are demonstrated in three planes: sagittal section (left), axial section (middle), and coronal section (right)

On the third day of hospitalisation, it was found that the patient still could not recognise the names of family members and objects, but he could remember his name. Patients also have difficulty reading, writing, and calculating, and sometimes are confused about determining the right and left limbs. The patient can also not recognise his limbs, such as his fingers. The patient's symptoms were consistent with Gerstmann's syndrome (Figure 3).

On the eighth day of hospitalisation, the patient was evaluated by examining the Aphasia Test for Rehabilitation Information Diagnosis (TADIR) and was found to have a diagnosis of Anomic Aphasia (Table 1). During the evaluation, he could remember the names of family and friends but still had difficulty understanding the names of objects. Patients also still have difficulty reading and recognising fingers and are wrong when asked to follow orders to raise their arms or legs in a specific position (left-right disorientation). The patient was sent home with an improved condition and routine check-ups in the neurology outpatient clinic.



**Figure 3.** Brain Magnetic Resonance Imaging (MRI) and Angiography (MRA) showed no detectable macrovascular abnormalities one year after symptom onset. Images: Brain MRA [A]; T2-weighted Brain MRI [B]

**Table 1.** TADIR (Indonesian Aphasia Test) result

Variable	Results/score
<b>Speech</b>	
Personal Information	4
Mention	2
<b>Naming</b>	
Words	3
Sentences	3
<b>Tell a Story</b>	
Read aloud	5
Imitate speech	5
<b>Understanding Spoken Language</b>	
Words	4
Sentences	2
Total Score	4
<b>Understanding Written Language</b>	
Words	2
Sentences	0
Total score	1
Personal information	3
<b>Writing</b>	
Personal information	3
Dictation	5
Words	3
Sentences	3
<b>Aphasia diagnose</b>	Yes
<b>Aphasia syndrome</b>	Anomic Aphasia

## Discussion

Aphasia is the loss or disruption of production and comprehension of spoken or written language due to lesions in the brain.<sup>6-8</sup> One type of aphasia is rarely found, such as anomic aphasia.<sup>6-9</sup>

In anomic aphasia, patients tend to stammer when saying objects, tend to group them into groups, or try to find another name or function of an object. The patient also cannot name an object that is already and easily recognized, in contrast to common aphasia, where patients tend to make errors in paraphrasing or use other words that are difficult to recognize. In anomic aphasia, patients can speak fluently, understand or be comprehensive in language, and repeat words or phrases well. Anomic aphasia patients can also spell well.<sup>6,8,10</sup>

Anomic aphasia is often associated with lesions in several language areas, most commonly in the temporal lobe of the dominant (left) hemisphere. Lesions tend to be located in the basal part of the posterior temporal or medial temporal lobe, where this position is close to the connection between the sensory language area and

the hippocampal region, as an area of memory and learning. Anomic aphasia often occurs due to occlusion of the temporal branch of the posterior cerebral artery. Anomics is often associated with Gerstmann's syndrome, where lesions occur in the frontal lobe and angular gyrus.<sup>8</sup>

The location of the lesion in anomic aphasia is still debated today. Many studies have examined the location of lesions in anomic aphasia, but no definite location can explain these symptoms. Although many studies state that the parietal lobe is the primary lesion site for anomic aphasia, many believe that Broca's or Wernicke's area is the leading cause.<sup>10</sup>

Døli et al.<sup>11</sup> A study regarding the type of aphasia with the location of the lesion in stroke patients found that lesions in the frontal lobe, especially the orbital pars insula, and lesions in the temporal lobe, especially parts of the Heschl gyrus and superior temporal gyrus, are associated with difficulties in naming (naming subtest).<sup>11</sup> The insula is thought to be essential in coordinating language production and comprehension. Meanwhile, the superior temporal gyrus plays a role in speech processing, especially speech perception and recognition.

One of the most frequent causes of Aphasia is vascular disorders, including intracerebral hemorrhages, such as stroke. Hemorrhagic stroke can be caused by primary causes such as hypertension, angiopathy, and cerebral amyloid angiopathy. Secondary causes that can cause Hemorrhagic stroke are Arteriovenous malformation, Aneurysm, Cavernous angioma, or Moyamoya disease.<sup>12,13</sup>

Gerstmann syndrome is a rare and unique case.<sup>2,14,15</sup> Gerstmann syndrome includes acalculia or counting disorders, finger agnosia or the patient's inability to recognize his or other people's fingers, left-right disorientation, and semantic aphasia.<sup>16</sup> Gerstmann syndrome is associated with lesions in the dominant hemisphere, especially the angular gyrus of the parietal lobe.<sup>4,17,18</sup>

The angular gyrus is associated with the location of the lesion. However, there are reports of similar clinical symptoms with different locations of lesions, such as on the medial aspect of the frontal lobe.<sup>2,19</sup> The angular gyrus changes images of letters and words into meaningful information, such as reading.<sup>19-21</sup>

Lesions in the gyrus are associated with agraphia and acalculia.<sup>4,22</sup> In addition, damage to the anterior temporal lobe is associated with naming disorders in familiar people.<sup>23,24</sup> If the lesion extends to the superior parietal gyrus, symptoms of agraphia can be found.<sup>4</sup>

In this case, the patient suddenly complained of not remembering the name of the person he recognized. He also could not recognize the object's name, but understood its function. The patient also has difficulty

reading and recognizing fingers. He appears confused and makes mistakes when asked to move his hands or feet on one side (right and left disorientation). In this case, there were all the symptoms of Gerstmann's Syndrome plus anomic aphasia.

The TADIR test is the first aphasia detection tool that has become standard in Indonesia. The TADIR test has four objectives that can be obtained from a combination of existing subtests. The purpose of 1) is to diagnose whether someone has aphasia or not, 2) to find out the type of aphasia syndrome suffered, 3) to provide information about the patient's condition to the patient, the patient's environment, and other individuals or agencies related to the patient, and 4) to obtain essential therapy and rehabilitation.<sup>25</sup>

Tests for aim 1) include object naming and speaking fluency. For the second purpose, subtests assess the patient's speech speed, from spontaneous speech to auditory comprehension, by pointing to pictures and repeating words and sentences. To assess objectives 3) and 4) using all tests. However, the TADIR test cannot reveal the severity of the patient's aphasia.<sup>25</sup> In this case, the TADIR test was carried out. The first objective was that the patient had aphasia. The second subtest found that the patient had an aphasia syndrome in the form of anomic aphasia.

## Conclusion

In conclusion, our case study underscores the importance of a comprehensive examination in every instance of aphasia. The coexistence of anomic aphasia with Gerstmann's Syndrome can significantly impact a patient's daily life. Therefore, a thorough examination is recommended to ensure early detection and appropriate intervention.

## References

1. Durand E, Berroir P, Ansaldo AI. The Neural and Behavioral Correlates of Anomia Recovery following Personalized Observation, Execution, and Mental Imagery Therapy: A Proof of Concept. *Neural Plast*; 2018. DOI: 10.1155/2018/5943759
2. Ardila A. Gerstmann Syndrome. *Current Neurology and Neuroscience Reports*. Springer; 2020. DOI: 10.1007/s11910-020-01069-9
3. Feng HM, Kuo SC, Chen Chun-Yen, Yeh YW. Rapidly Progressive Anomic Aphasia: A Rare Presentation of Temporal Lobe Tumor. *Journal Neuropsychiatry Clinical Neuroscience*; 2015. 25(2). DOI: 10.1176/appi.neuropsych.12030067
4. Patil VC, Kulkarni AR. Gerstmann's Syndrome: A Rare Clinical Condition with a Tetrad of Symptoms. *International Journal of Contemporary Medicine, Surgery and Radiology*; 2019. 4(2). DOI: 10.21276/ijemsr.2019.4.2.38
5. Rusconi E. Gerstmann syndrome: historic and current perspectives. In: *Handbook of Clinical Neurology*. Elsevier B.V.; 2018. p. 395–411.
6. Fridriksson J, Hillis AE. Current approaches to the treatment of post-stroke aphasia. *Journal of Stroke*. Korean Stroke Society; 2021. 23:183–201. DOI: 10.5853/jos.2020.05015
7. Catania V, D'Angelo G, Panerai S, Lanuzza B, Ferri R. Case report: Applied behavior analysis in a case of anomic aphasia in post-acute myocardial infarction with cardiac arrest and brain hypoxia: results of tact-training. *Front Psychol*; 2024. p. 15. DOI: 10.3389/fpsyg.2024.1407399
8. Ropper AH, Samuels MA, Klein JP, Prasad S. Disorders of Speech and Language. In: *Adams and Victor's Principles of Neurology*. 12th ed. McGraw-Hill Professional; 2023. p. 489.
9. Vitali P, Rouleau I, Deschaintre Y, Mina D, Brazeau M, Lanthier S, et al. Proper name anomia in poststroke aphasics: evidence from a multiple-case study. *Neurocase*; 2015. 3;21(5):563–72. DOI: 10.1080/13554794.2014.959974
10. Wang, Zhemin & Tng, Eng Loon. Neuroglycopenia presenting as isolated aphasia. *Journal of Clinical and Translational Endocrinology: Case Reports*; 2021. 21:100089. DOI: 10.1016/j.jecr.2021.100089
11. Døli H, Andersen Helland W, Helland T, Specht K. Associations between lesion size, lesion location, and aphasia in acute stroke. *Aphasiology*; 2021. 35(6):745–63. DOI: 10.1080/02687038.2020.1727838
12. Magid-Bernstein J, Girard R, Polster S, Srinath A, Romanos S, Awad IA, et al. Cerebral hemorrhage: Pathophysiology, treatment, and future directions. *Circ Res*; 2022. 130(8):1204–29. DOI: 10.1161/CIRCRESAHA.121.319949
13. Lui F, Alcaide J, Knowlton S, Ysit M, Zhong N. Pathogenesis of cerebral amyloid angiopathy caused by chaotic glymphatics—Mini-review. *Frontiers in Neuroscience*. Frontiers Media SA; 2023. DOI: 10.3389/fnins.2023.1180237
14. Basagni B, Luzzatti C, De Tanti A, Bozzetti F, Crisi G, Pinardi C, et al. Some evidence on Gerstmann's syndrome: A case study on a variant of the clinical disorder. *Brain Cogn*; 2021. 1:148. DOI: 10.1016/j.bandc.2020.105679
15. Alare K, Abioye E, Saydo B. Gerstmann Syndrome: What is the Possible Role of Deep Brain Stimulation? *Neurocrit Care*; 2024. DOI: 10.1007/s12028-024-02013-2
16. Sandhya K. Effectiveness of speech and language therapy and spontaneous recovery in anomic aphasia. *Journal of Cerebrovascular Sciences*; 2020. 8(2):101. DOI: 10.4103/jcv.s.jcv.s\_11\_20

17. Nicastro N, Tafer N, Schnider A, Di Pietro M. Gerstmann's syndrome associated with right parietal hemorrhage and arteriovenous malformation. *Journal of Clinical Neurology (Korea)*. Korean Neurological Association; 2017. 13:306–7. DOI: 10.3988/jcn.2017.13.3.306
18. Toader C, Covache-Busuioc RA, Rădoi PM, Covlea CA, Popa AA, Dumitrascu DI, et al. Gerstmann Syndrome in an Elderly Patient: A Case Report Presented with a Complete Tetrad of Symptoms. *Medicina (Lithuania)*; 2024. 60(10). DOI: 10.3390/medicina60101640
19. Rockland KS, Graves WW. The angular gyrus is a special issue due to its complex anatomy and function. *Brain Structure and Function*. Springer Science and Business Media Deutschland GmbH; 2023. 28:1–5. DOI: 10.1007/s00429-022-02596-6
20. Dimitrov I, Kaprelyan A, Atanasova S, Drenska K. Gerstmann syndrome in a young man: a case report. *Trakia Journal of Sciences*; 2018. 16(3):239-241. DOI: 10.15547/tjs.2018.03.011
21. Zhao X, Riccardi N, Desai RH, Ouden DB den, Fridriksson J, Wang Y. Network-based Statistics Distinguish Anomic and Broca Aphasia. *arXiv*; 2023. DOI: 10.48550/arXiv.2302.03250
22. João RB, Filgueiras RM, Mussi ML, de Barros JEF. Transient Gerstmann syndrome as a manifestation of stroke: Case report and brief literature review. *Dementia e Neuropsychologia*. Academia Brasileira de Neurologia; 2017. 11:202–5. DOI: 10.1590/1980-57642016dn11-020013
23. Nikitha M, Darshan HS, Abhishek BP, Goswami SP. Clinical Profiling of a Bilingual Client with Anomic Aphasia. *Ann Neurosci*; 2020. 27(2):75–82. DOI: 10.1177/0972753120927518
24. Salih Al-Samaraie AA. Gerstmann Syndrome Case-Control Study: Correlation between Brain Lesions & Functional Disability. *International Tinnitus Journal*; 2023. 27(2):247–52. DOI: 10.5935/0946-5448.20230038
25. Jap BAJ, Arumsari C. Adaptation of the Token Test in Standard Indonesian. *Makara Human Behavior Studies in Asia*; 2017. 21(1):44. DOI: 10.7454/mssh.v21i1.3499