



CHARACTERISTICS OF OCULAR FUNDUS IN BRAIN INFECTIONS AT CIPTO MANGUNKUSUMO HOSPITAL JAKARTA

Maria Jheny Fulgensia Purba*, Pradita Sari, Septiana Andri Wardana, Ni Nengah Rida Ariarini, Kartika Maharani, Darma Imran, Riwanti Estiasari

*Correspondence: mariajhenypurba@gmail.com

Department of Neurology, Faculty of Medicine, Universitas Indonesia, Jakarta, Indonesia

Article History:

Received: May 3, 2023
Accepted: June 21, 2023
Published: July 1, 2023

Cite this as:

Purba MJF, Sari P, Wardana SA, Ariarini NN R, Maharani K, Imran D, Estiasari R. Characteristics of Ocular Fundus in Brain Infections at Cipto Mangunkusumo Hospital Jakarta. *Magna Neurologica*. 1(2) July 2023: 49-53. 10.20961/magnaneurologica.v1i2.716

ABSTRACT

Background: Brain infections (BI) may cause optic nerve abnormalities. Awareness on optic nerve abnormalities will be useful in assisting further management. The characteristics of the ocular fundus (fundus) in BI have not been widely studied in Indonesia.

Objective: This study aimed to apprehend the depiction of the fundus in BI in Cipto Mangunkusumo Hospital Jakarta (RSCM).

Methods: Cross-sectional study was conducted on October-December 2021 at RSCM. Inclusion criteria: BI patients who had fundas results. Exclusion criteria: fundas results cannot be interpreted. Images from 20D-lens fundoscopy were captured with a digital camera. Captured images were then interpreted by three examiners in disguise. Results are analyzed if there are similarities between at least two examiners.

Results: There were 49 subjects whose fundoscopy results could be analyzed. A total of 25 subjects has normal fundus. Abnormalities were seen in 8 subjects, which comprised of 4 (12.1%) papilledema, 3 (9.1%) papillatrophy and 1 (3%) retinal haemorrhage. The highest mean aperture pressure was found in the papillatrophy group (37cmH₂O), followed by papilledema (27cmH₂O). BI that often causes papilledema (60%) is cryptococcal meningitis. Of all BI that ended up with mortality, 80% were tuberculous meningitis with normal fundus on examination. BI can increase intracranial pressure (ICP). Nonetheless, we found only 12.1% had papilledema. The highest mean aperture pressure was found in the papillatrophy group which showed an increase in ICP over a long period of time. The highest mortality was found in the normal fundus group so that papilledema cannot be directly associated with a worse prognosis considering the uncontrolled confounding factors such as other BI complications.

Conclusion: Although BI causes an increase in ICP, papilledema is not always found. High aperture pressure was found in the papillatrophy group, but the highest mortality was found in the normal fundus group.

Keywords: fundus oculi, intracranial infection, normal fundus, papilledema

Introduction

CNS infections are known to cause optic nerve abnormalities and other retinal abnormalities.³ Fundoscopic examination is the basis for diagnosing lesions in the posterior eye segment either due to abnormalities in the eye itself or eye complications due to systemic disease which can reflect various pathologies that occur in the brain.⁴ Information on abnormalities in the fundus and retina will certainly be

useful in assisting in determining the diagnosis or further management.

The characteristics of the ocular fundus in cases of brain infection (BI) have not been widely studied in Indonesia, despite its potential significance in understanding disease progression and diagnosis. Therefore, this study aimed to comprehensively investigate and analyze the appearance of the ocular fundus in patients with CNS infections at Cipto Mangunkusumo Hospital (RSCM).

Methods

A cross-sectional study was conducted over a three-month period, from October 2021 to December 2021, at Cipto Mangunkusumo National General Hospital (RSCM), involving patients diagnosed with brain infections (BI) who were undergoing treatment at the hospital. The inclusion criteria for this study were patients diagnosed with brain infections who had documented fundus examination results, while the exclusion criterion was applied to patients whose fundus examination results were deemed uninterpretable. Fundoscopic examinations were performed using a 20-diopter lens, and the findings were recorded using a mobile phone camera for documentation purposes. These video recordings were subsequently evaluated and interpreted independently by three examiners, who were blinded to both the patients' identities and the interpretation results provided by the other examiners. The final interpretation results were compiled, and the data were considered valid and included for analysis only if there was consensus in the interpretation of the ocular fundus findings among at least two of the three examiners.

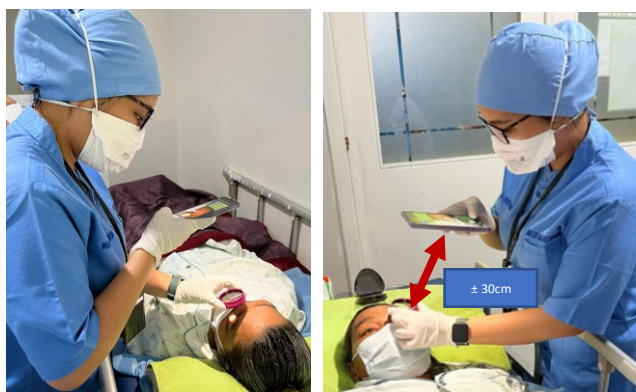


Figure 1. Indirect fundoscopic examination

Results

Out of the total 33 patients diagnosed with intracranial infection, 25 patients (75.8%) demonstrated normal findings during the fundus examination, indicating no visible abnormalities. In contrast, 8 patients (24.2%) exhibited abnormal fundus results, which included a range of specific conditions. Among these abnormal findings, 4 patients (12.1%) were identified with papilledema, a condition characterized by swelling of the optic disc due to increased intracranial pressure. Additionally, 3 patients (9.1%) showed evidence of papillatrophy, indicating optic nerve damage and atrophy, while 1 patient (3%) presented with retinal hemorrhage, a condition marked by bleeding in the retinal tissue. These findings are summarized and visually represented in figure 1.

Table 1. Fundus findings and clinical data

Clinical Presentation	Normal fundus (N=25)	Papilledema (N=4)	Papillatrophy (N=3)
GCS at admission*	13.24	13.75	13.7
History of headache	87.5%	12.5%	0%
Seizure	83.3%	16.7%	0%
Loss of consciousness	73.3%	13.3%	13.3%
HIV	32%	100%	33.3%
Onset			
- Acute	64%	75%	100%
- Chronic	36%	25%	0%
Lumbar Puncture			
Opening pressure (cmH ₂ O)*	19	27	37
Cell count*	202.96	43	42.67
Protein (mg/dL)*	213.74	119	98.33
Glucosa ratio	34.4%	47%	55%
Diagnosis			
- Toxoplasmic encephalitis	100%	0%	0%
- Tuberculosis meningitis	85.7%	4.8%	9.5%
- Cryptococcal meningitis	33.3%	60%	0%
- Others	80%	0%	20%
Outcome			
- Survive	75%	10.7%	10.7%
- Death	80%	20%	0%

The group of patients with normal fundus results had an average opening pressure during the lumbar puncture (LP) procedure of 19 cmH₂O. In comparison, the group of patients presenting with papilledema had a higher average opening pressure of 27 cmH₂O, while the patients with papillatrophy exhibited the highest average opening pressure, reaching 37 cmH₂O (Figure 2).

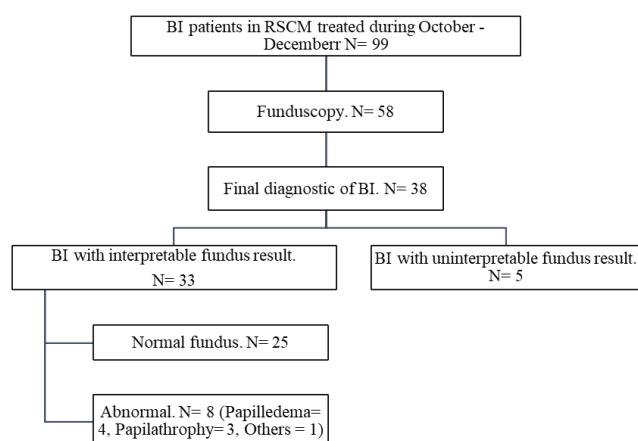


Figure 2. Results of examination of the ocular fundus in BI patients for the period October-December 2021

Discussion

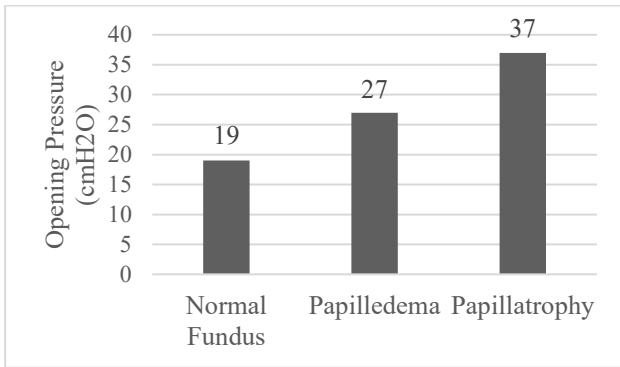


Figure 3. An overview of the ocular fundus based on the opening pressure at the lumbar puncture

From the results of the study, it was found that 100% of patients with a toxoplasma encephalitis had a normal fundus (Figure 3). In TB meningitis 85.7% patients had normal fundus, 4.8% papilledema and 9.5% papillatrophy. Cryptococcal meningitis patients 33.3% had normal fundus, 60% papilledema and 16.7% retinal haemorrhage (Figure 4).

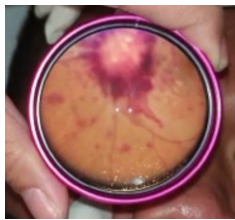


Figure 4. Retinal hemorrhage in cryptococcal meningitis patient

Of the 25 BI patients with normal fundus results, the average GCS at admission was 13.24, with clinical symptoms of headache experienced by 7 (28%) patients. The average opening pressure during lumbar puncture (LP) was 19 cmH₂O, with the results of cerebrospinal fluid (CSS) analysis: the average cell number was 202.96 cells/ μ L, the average protein was 213.75 mg/dL and the ratio of CSS: serum glucose was 34.4%. Out of 4 brain infection patients with papilledema, the average GCS at admission was 13.75, with clinical symptoms of headache experienced by 1 (25%) patient. The average opening pressure during LP was 27 cmH₂O with of cerebrospinal fluid (CSS) analysis results showing an average cell count of 43 cells/ μ L, an average protein of 119 mg/dL, and a ratio of CSS: serum glucose of 47%. Of the 3 brain infection patients with papillatrophy, the mean GCS at admission was 13.7. The average opening pressure during LP was 37 cmH₂O, with the results of CSS analysis in the form of an average cell number of 42.67 cells/ μ L, an average protein of 98.33 mg/dL and a ratio of CSS: serum glucose of 55%.

In a cross-sectional study conducted to study the picture of the ocular fundus in patients with brain infections at RSCM, it was shown that the majority (75.8%) of the patients had normal fundus results. Brain infections cause increased intracranial pressure and papilledema or other retinal abnormalities.³ However, in this study, only 12.1% of patients with BI had papilledema. Papilledema is the most common in cases of cryptococcal meningitis (60%). The presence of papilledema in a patient with neurologic deficits suggests a secondary cause and requires immediate further evaluation as it indicates an increased intracranial pressure (ICP). Increased ICP in patients with brain infection may result from either or a combination of increased amount of intracranial tissue mass by space-occupying lesions (e.g., tuberculoma, toxoplasma encephalitis), increased intracranial tissue volume by focal or diffuse cerebral edema, decreased absorption of CSF from the cerebrospinal system. Ventricles (e.g., communicating, or non-communicating hydrocephalus) or in arachnoid granulations (e.g., meningitis).⁵

In this study, the most common diagnoses in patients with BI in the Neurology ward at RSCM were tuberculosis meningitis (TBM), followed by cryptococcal meningitis and toxoplasma encephalitis. TBM is the most severe form of tuberculosis infection and nearly 70% of tuberculosis infection affecting the nervous system occurs as TBM form.⁶ TBM patients may experience papilledema and abducens nerve paresis which are associated with increased ICP. A study in India on ophthalmological manifestations of 101 TBM patients showed that 23 (22.8%) patients had papilledema and 3 (3%) atrophic papillary.⁷ In contrast to this study (4.8%) and other literature reports that the frequency of papilledema in TBM cases is very small and usually very mild and transient. In a study of 2178 patients with meningitis, only 2.5% had papilledema of the ocular fundus.⁸ The most common causes of papilledema in TBM cases are space-occupying lesions (tuberculoma), cerebral venous thrombosis and involvement of the meninges which causes an increase in ICP. The primary papilledema does not cause visual disturbances unless it is followed by secondary papillatrophy.¹⁹ Papillatrophy in TBM can be caused by opto-chiasmatic arachnoiditis which causes compression and stretching of the optic nerve.⁷ In this study 2 (9.5%) patients with TBM had papillatrophy results.

Cryptococcal meningitis can also cause visual disturbances caused by papilledema. The mechanism causing papilledema is associated with increased ICP or direct invasion of the optic nerve by cryptococci.^{9,18} In this study, 60% of cryptococcal meningitis patients had papilledema. Decompression of the optic nerve is

a treatment option for visual impairment, especially if increased ICP causes it.

Toxoplasmosis is an infection caused by *Toxoplasma gondii* often associated with immune deficiency. *T. gondii* can reach the CNS, cause brain infections (toxoplasmosis encephalitis) and reach the retina (ocular toxoplasmosis).²⁰ Ocular toxoplasmosis is characterized by subacute visual disturbances with papilledema and in some cases an active lesion that appears as a macular star (neuro-retinitis).^{10,11} In this study, all patients with toxoplasma encephalitis had a normal ocular fundus appearance and no visual disturbances indicating that the infection did not reach the retina.

In this study, headache was the most common complaint (100%) in patients with papilledema. The presence of papilledema in a patient with headache indicates a secondary cause and requires immediate further management.¹³ The highest mean opening pressure (37 cmH₂O) was found in the papillatroph group indicating that increased intracranial pressure may occur in the long term.¹⁴ A study in India regarding ophthalmological manifestations in patients with TBM concluded that papilledema is associated with poor clinical outcomes.^{7,12} However, in this study, normal fundus group had the highest mortality. Papilledema cannot be directly associated with a worse prognosis because there are still uncontrolled confounding factors, such as other complications of the disease.¹⁵

In this study, a fundus examination was carried out using indirect funduscopy. The patient was positioned at arm's length away from the examiner, after mydriatics were used to dilate the pupils. Then a 20-diopter lens was set in front of the patient's eyes. The lens can be directed towards or away from the patient's eyes to enhance visualization and thus the examiner does not need to get too close to the patient and the scope of view is wider. The benefit of this study was that as far as the examiner knew, there had never been a study regarding the characteristics of ocular fundus in brain infection.¹⁷ Meanwhile, the results were recorded and can be played back repeatedly, allowing doctor-patient thorough discussion. However, the recorded results are strongly influenced by the examiner's ability, and thus became a weakness in this study.

Conclusion

Although CNS infection can cause an increase in ICP, papilledema is not always present. High opening pressure was found in the atrophic papillary group but the highest mortality was found in the normal fundus group. Nevertheless, further research is still needed with a larger sample. The availability of indirect

funduscopy will facilitate easier and more frequent ocular fundus examination in brain infection patients.

References

1. Imran D, Estiasari R, Maharani K, Sucipto, Lestari DC, Yunus RE, et al. Presentation, etiology, and outcome of brain infections in an Indonesian hospital: A cohort study. *Neurol Clin Pract*; 2018 Oct. 8(5):379–88. Retrieved on Mar 4, 2023. Available from: <https://pubmed.ncbi.nlm.nih.gov/30564491>
2. Imran D, Satiti S, Sugianto P, Estiasari R, Maharani K, Pangeran D, et al. Barriers to diagnosis and management of CNS infections in Indonesia. *Neurology*; 2019 Jan. 92(2):104–6. Retrieved on Mar 4, 2023. Available from: <http://n.neurology.org/content/92/2/104.abstract>
3. Pachapure DS, B S DM, T Achar DM. Occurrence of Ocular Fundal Changes in Cases of Infective Meningitis and Meningoencephalitis in Our Hospital. *IOSR J Dent Med Sci*; 2014. 13(1):54–9. Retrieved on Mar 4, 2023. Available from: <https://www.iosrjournals.org/iosr-jdms/papers/Vol13-issue1/Version-8/L013185459.pdf>
4. Sachdeva V, Vasseneix C, Hage R, Bidot S, Clough LC, Wright DW, et al. Optic nerve head edema among patients presenting to the emergency department. *Neurology*; 2018. 90(5):e373–9. DOI: 10.1212/WNL.0000000000004895
5. Mortensen PW, Wong TY, Milea D, Lee AG. The eye is a window to systemic and neuro-ophthalmic diseases. *Asia Pac J Ophthalmol (Phila)*; 2022 Mar-Apr. 11(2):91-93. DOI: 10.1097/APO.0000000000000531
6. Gu J, Xiao H, Wu F, Ge Y, Ma J, Sun W. Prognostic factors of tuberculous meningitis: a single-center study. *Int J Clin Exp Med*; 2015 Mar. 8(3):4487–93. Retrieved on Mar 4, 2023. Available from: <https://pubmed.ncbi.nlm.nih.gov/26064373>
7. Verma R, Sarkar S, Garg RK, Malhotra HS, Sharma PK, Saxena S. Ophthalmological manifestation in patients of tuberculous meningitis. *Qjm*; 2019. 112(6):409–19. DOI: 10.1093/qjmed/hcz037
8. Xie JS, Donaldson L, Margolin E. Papilledema: A review of etiology, pathophysiology, diagnosis, and management. *Surv Ophthalmol*; 2022 Jul-Aug. 67(4):1135-1159. DOI: 10.1016/j.survophthal.2021.11.007
9. Reier L, Fowler JB, Arshad M, Hadi H, Whitney E, Farmah AV, Siddiqi J. Optic Disc Edema and Elevated Intracranial Pressure (ICP): A Comprehensive Review of Papilledema. *Cureus*; 2022 May. 14(5):e24915. DOI: 10.7759/cureus.24915
10. Park Y-H, Nam H-W. Clinical features and treatment of ocular toxoplasmosis. *Korean J Parasitol*; 2013.

- 51(4):393–9. Retrieved on Mar 4, 2023. Available from: <https://pubmed.ncbi.nlm.nih.gov/24039281>
11. Greenlee JE. Approach to diagnosis of central nervous system infections. *Handb Clin Neurol*; 2016. 138:1–17.
 12. Thakur KT, Motta M, Cummins NW, Jordan B, Aseffa G, Birbeck GL. Global infectious diseases of the nervous system. *Semin Neurol*; 2018. 38(3):306–22. Retrieved on Mar 4, 2023. Available from: <https://lp.thieme.de/journals/neurology>
 13. Mai NTH, Chau TTH, Phu NH, et al. The role of the optic fundus in the diagnosis and management of tuberculous meningitis. *J Infect Dis*; 2018. 218(7):1086–94. Retrieved on Mar 4, 2023. Available from: [pmc.ncbi.nlm.nih.gov/articles/PMC10707096/](https://pubmed.ncbi.nlm.nih.gov/articles/PMC10707096/)
 14. Mishra AK, Arvind VH, Muliyl D, George B, Muthiah R, et al. Evaluation of fundoscopic changes in adult tuberculous meningitis. *J Neurol Sci*; 2019. 400:24–30. Retrieved on Mar 4, 2023. Available from: [pmc.ncbi.nlm.nih.gov/articles/PMC10707096/](https://pubmed.ncbi.nlm.nih.gov/articles/PMC10707096/)
 15. Koekkoek JA, Van Run PE, Van der Ende A, Brouwer MC, Van de Beek D. Cranial nerve palsies in adults with community-acquired bacterial meningitis. *Neurology*; 2017. 88(7):570–7. DOI: 10.1212/WNL.0000000000003650
 16. He G, Dunn HP, Ahmad KE, Watson E, Henderson A, Tynan D, Leaney J, White AJ, Hewitt AW, Fraser CL. Fundoscopy use in neurology departments and the utility of smartphone photography: a prospective prevalence and crossover diagnostic accuracy study amongst neurology inpatients. *Eur J Neurol*; 2022 Aug. 29(8):2463–2472. DOI: 10.1111/ene.15390.
 17. Feng G, Zhou L, Li F, Hu Y, Wang X, Tian X. Predictors of Outcome in Clinically Diagnosed Viral Encephalitis Patients: A 5-Year Prospective Study. *Biomed Res Int*; 2020 Jul. 2020:2832418. DOI: 10.1155/2020/2832418
 18. Zhu L, Wang Z, Zhang K, et al. Clinical spectrum and treatment of intracranial hypertension in infectious meningitis. *Med (Baltimore)*; 2019. 98(35):e16864. DOI: 10.1097/MD.00000000000016864
 19. Albert DM, Raven ML. Ocular Tuberculosis. *Microbiol Spectr*; 2016 Nov. 4(6):10. DOI: 10.1128/microbiolspec.TNMI7-0001-2016.
 20. Kotlus BS, Slavin ML, Guthrie DS, Kodsi SR. Ophthalmologic manifestations in pediatric patients with acute disseminated encephalomyelitis. *J AAPOS*. 2005 Apr. 9(2):179–83. DOI: 10.1016/j.jaapos.2004.10.009