



CHARACTERISTICS OF OCULAR FUNDUS IN BRAIN INFECTIONS AT CIPTO MANGUNKUSUMO HOSPITAL JAKARTA

Maria Jheny Fulgensia Purba¹, Pradita Sari², Septiana Andri Wardana³, Ni Nengah Rida Ariarini⁴, Kartika Maharani⁵, Darma Imran⁶, Riwanti Estiasari⁷

Correspondence: mariajhenypurba@gmail.com

¹Department of Neurology, Faculty of Medicine, University of Indonesia, Cipto Mangunkusumo Hospital, Jakarta, Indonesia

²Department of Neurology, Faculty of Medicine, University of Indonesia, Cipto Mangunkusumo Hospital, Jakarta, Indonesia

³Department of Neurology, Faculty of Medicine, University of Indonesia, Cipto Mangunkusumo Hospital, Jakarta, Indonesia

⁴Department of Neurology, Faculty of Medicine, University of Indonesia, Cipto Mangunkusumo Hospital, Jakarta, Indonesia

⁵Department of Neurology, Faculty of Medicine, University of Indonesia, Cipto Mangunkusumo Hospital, Jakarta, Indonesia

⁶Department of Neurology, Faculty of Medicine, University of Indonesia, Cipto Mangunkusumo Hospital, Jakarta, Indonesia

⁷Department of Neurology, Faculty of Medicine, University of Indonesia, Cipto Mangunkusumo Hospital, Jakarta, Indonesia

Article History:

Received: May 3, 2023

Accepted: June 21, 2023

Published: July 1, 2023

Cite this as: Vancouver style

Purba M J F, Sari P, Wardana S A, Ariarini N N R, Maharani K, Imran D, Estiasari R. Characteristics Of Ocular Fundus In Brain Infections At Cipto Mangunkusumo Hospital Jakarta. *Magna Neurologica*. 1 (2) July 2023:44-48., 10.20961/magnaneurologica.v1i2.716

ABSTRACT

Background: Brain infections (BI) may cause optic nerve abnormalities. Awareness on optic nerve abnormalities will be useful in assisting further management. The characteristics of the ocular fundus (fundus) in BI have not been widely studied in Indonesia. This study aimed to apprehend the depiction of the fundus in BI in Cipto Mangunkusumo Hospital Jakarta (RSCM).

Methods: Cross-sectional study was conducted on October-December 2021 at RSCM. Inclusion criteria: BI patients who had fundas results. Exclusion criteria: fundas results cannot be interpreted. Images from 20D-lens fundoscopy were captured with a digital camera. Captured images were then interpreted by three examiners in disguise. Results are analyzed if there are similarities between at least two examiners.

Results: There were 49 subjects whose fundoscopy results could be analyzed. A total of 25 subjects has normal fundus. Abnormalities were seen in 8 subjects, which comprised of 4 (12.1%) papilledema, 3 (9.1%) papillatrophy and 1 (3%) retinal haemorrhage. The highest mean aperture pressure was found in the papillatrophy group (37cmH₂O), followed by papilledema (27cmH₂O). BI that often causes papilledema (60%) is cryptococcal meningitis. Of all BI that ended up with mortality, 80% were tuberculous meningitis with normal fundus on examination.

Discussion: BI can increase intracranial pressure (ICP). Nonetheless, we found only 12.1% had papilledema. The highest mean aperture pressure was found in the papillatrophy group which showed an increase in ICP over a long period of time. The highest mortality was found in the normal fundus group so that papilledema cannot be directly associated with a worse prognosis considering the uncontrolled confounding factors such as other BI complications.

Conclusion: Although BI causes an increase in ICP, papilledema is not always found. High aperture pressure was found in the papillatrophy group, but the highest mortality was found in the normal fundus group.

Keywords: Fundus Oculi, Intracranial Infection, Papilledema, Normal Fundus

Introduction

CNS infections are known to cause optic nerve abnormalities and other retinal abnormalities.³ Fundoscopic examination is the basis for diagnosing lesions in the posterior eye segment either due to abnormalities in the eye itself or eye complications due to systemic disease which can reflect various pathologies that occur in the brain.⁴ Information on abnormalities in the fundus and retina will certainly be useful

in assisting in determining the diagnosis or further management. The characteristics of the ocular fundus in cases of brain infection (BI) have not been widely studied in Indonesia. This study aimed to study the appearance of the ocular fundus in CNS infections in the hospital Cipto Mangunkusumo Jakarta (RSCM).

Methods

A cross-sectional study was conducted from October 2021 to December 2021 at RSCM which included BI patients treated at RSCM. The inclusion criteria were BI patients who had fundus results and the exclusion criteria was patients with uninterpretable fundus results. Fundoscopic examination was carried out using a 20-diopter lens and recorded with a mobile phone camera. The video recordings were then interpreted by three examiners without knowing the patient's identity and the inter-examiner interpretation results. Interpretation results are collected and data will be analyzed if there are similarities in the interpretation of the ocular fundus from at least two examiners.

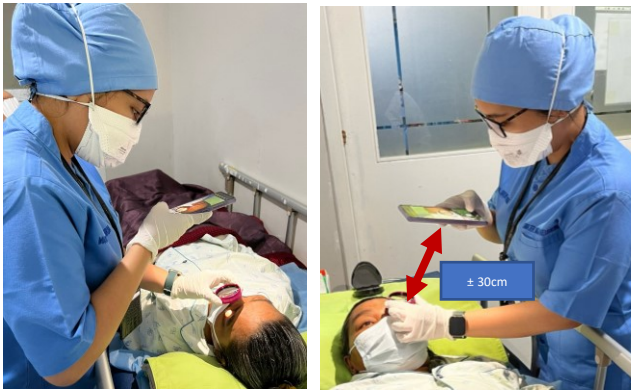

Figure 1. Indirect fundoscopic examination

Results

	Normal fundus (N=25)	Papilledema (N=4)	Papillatrophy (N=3)
GCS at admission*	13.24	13.75	13.7
History of headache	87.5%	12.5%	0%
Seizure	83.3%	16.7%	0%
Loss of consciousness	73.3%	13.3%	13.3%
HIV	32%	100%	33.3%
Onset			
- Acute	64%	75%	100%
- Chronic	36%	25%	0%
Lumbar Puncture			
Opening pressure (cmH ₂ O)*	19	27	37
Cell count*	202.96	43	42.67
Protein (mg/dL)*	213.74	119	98.33
Glucosa ratio	34.4%	47%	55%
Diagnosis			
- Toxoplasmic encephalitis	100%	0%	0%
- Tuberculosis meningitis	85.7%	4.8%	9.5%
- Cryptococcal meningitis	33.3%	60%	0%
- Others	80%	0%	20%
Outcome			
- Survive	75%	10.7%	10.7%
- Death	80%	20%	0%

*mean

Of the 33 patients with intracranial infection, 25 patients (75.8%) had normal fundus results and 8 patients (24.2%) had abnormal fundus results (4 patients (12.1%) with papilledema, 3 patients (9.1%) papillatrophy and 1 patient (3%) with retinal hemorrhage) (Figure 1).

The group with normal fundus results had an average opening pressure in the LP procedure of 19 cmH₂O, in the group with papilledema was 27 cmH₂O and in patients with papillatrophy was 37 cmH₂O (Figure 2).

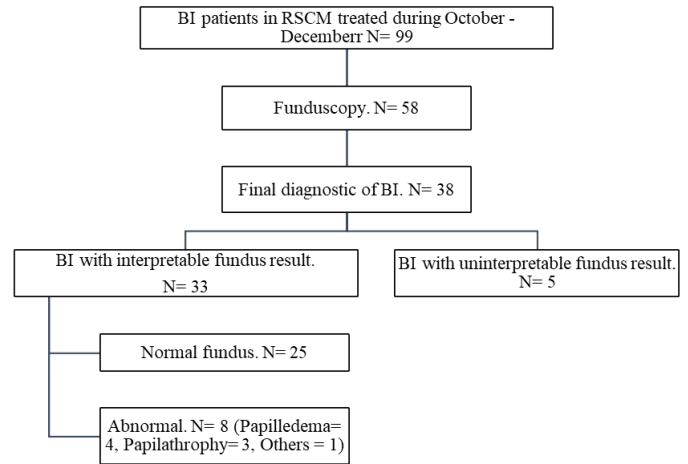


Figure 2. Results of examination of the ocular fundus in BI patients for the period October - December 2021

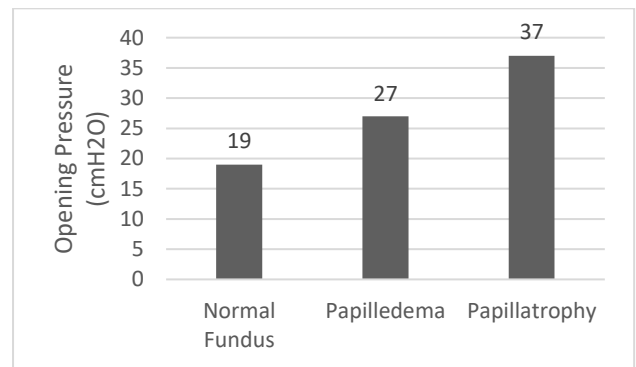


Figure 3. An overview of the ocular fundus based on the opening pressure at the lumbar puncture

From the results of the study, it was found that 100% of patients with a toxoplasma encephalitis had a normal fundus. In TB meningitis 85.7% patients had normal fundus, 4.8% papilledema and 9.5% papillatrophy. Cryptococcal meningitis patients 33.3% had normal fundus, 60% papilledema and 16.7% retinal haemorrhage.

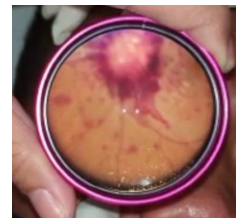


Figure 4. Retinal hemorrhage in cryptococcal meningitis patient

Of the 25 BI patients with normal fundus results, the average GCS at admission was 13.24, with clinical symptoms of headache experienced by 7 (28%) patients. The average opening pressure during lumbar puncture (LP) was 19 cmH₂O, with the results of cerebrospinal fluid (CSS) analysis: the average cell number was 202.96 cells/ μ L, the

average protein was 213.75 mg/dL and the ratio of CSS: serum glucose was 34.4%. Out of 4 brain infection patients with papilledema, the average GCS at admission was 13.75, with clinical symptoms of headache experienced by 1 (25%) patient. The average opening pressure during LP was 27 cmH₂O with of cerebrospinal fluid (CSS) analysis results showing an average cell count of 43 cells/ μ L, an average protein of 119 mg/dL, and a ratio of CSS: serum glucose of 47%. Of the 3 brain infection patients with papillatrophy, the mean GCS at admission was 13.7. The average opening pressure during LP was 37 cmH₂O, with the results of CSS analysis in the form of an average cell number of 42.67 cells/ μ L, an average protein of 98.33 mg/dL and a ratio of CSS: serum glucose of 55%.

Discussion

In a cross-sectional study conducted to study the picture of the ocular fundus in patients with brain infections at RSCM, it was shown that the majority (75.8%) of the patients had normal fundus results. Brain infections cause increased intracranial pressure and papilledema or other retinal abnormalities.³ However, in this study, only 12.1% of patients with BI had papilledema. Papilledema is the most common in cases of cryptococcal meningitis (60%). The presence of papilledema in a patient with neurologic deficits suggests a secondary cause and requires immediate further evaluation as it indicates an increased intracranial pressure (ICP). Increased ICP in patients with brain infection may result from either or a combination of increased amount of intracranial tissue mass by space-occupying lesions (e.g., tuberculoma, toxoplasma encephalitis), increased intracranial tissue volume by focal or diffuse cerebral edema, decreased absorption of CSF from the cerebrospinal system. ventricles (e.g., communicating, or non-communicating hydrocephalus) or in arachnoid granulations (e.g., meningitis).⁵

In this study, the most common diagnoses in patients with BI in the Neurology ward at RSCM were tuberculosis meningitis (TBM), followed by cryptococcal meningitis and toxoplasma encephalitis. TBM is the most severe form of tuberculosis infection and nearly 70% of tuberculosis infection affecting the nervous system occurs as TBM form.⁶ TBM patients may experience papilledema and abducens nerve paresis which are associated with increased ICP. A study in India on ophthalmological manifestations of 101 TBM patients showed that 23 (22.8%) patients had papilledema and 3 (3%) atrophic papillary.⁷ In contrast to this study (4.8%) and other literature reports that the frequency of papilledema in TBM cases is very small and usually very mild and transient. In a study of 2178 patients with meningitis, only 2.5% had papilledema of the ocular fundus.⁸ The most common causes of papilledema in TBM cases are space-occupying lesions (tuberculoma), cerebral venous thrombosis and involvement of the meninges which causes an increase in ICP. The primary papilledema does not cause visual disturbances unless it is followed by secondary papillatrophy. Papillatrophy in TBM can be caused by optochiasmatic arachnoiditis which causes compression and stretching of the optic nerve.⁷ In this study 2 (9.5%) patients with TBM had papillatrophy results.

Cryptococcal meningitis can also cause visual disturbances caused by papilledema. The mechanism causing papilledema is associated with increased ICP or direct invasion of the optic nerve by cryptococci.⁹ In this study, 60% of cryptococcal meningitis patients had papilledema. Decompression of the optic nerve is a treatment option for visual impairment, especially if increased ICP causes it.

Toxoplasmosis is an infection caused by *Toxoplasma gondii* often associated with immune deficiency. *T. gondii* can reach the CNS, cause brain infections (toxoplasmosis encephalitis) and reach the retina (ocular toxoplasmosis). Ocular toxoplasmosis is characterized by subacute visual disturbances with papilledema and in some cases an active lesion that appears as a macular star (neuro-retinitis).¹⁰ In this study, all patients with toxoplasma encephalitis had a normal ocular fundus appearance and no visual disturbances indicating that the infection did not reach the retina.

In this study, headache was the most common complaint (100%) in patients with papilledema. The presence of papilledema in a patient with headache indicates a secondary cause and requires immediate further management. The highest mean opening pressure (37 cmH₂O) was found in the papillatrophy group indicating that increased intracranial pressure may occur in the long term. A study in India regarding ophthalmological manifestations in patients with TBM concluded that papilledema is associated with poor clinical outcomes.⁷ However, in this study, normal fundus group had the highest mortality. Papilledema cannot be directly associated with a worse prognosis because there are still uncontrolled confounding factors, such as other complications of the disease.

In this study, a fundus examination was carried out using indirect funduscopy. The patient was positioned at arm's length away from the examiner, after mydriatics were used to dilate the pupils. Then a 20-diopter lens was set in front of the patient's eyes. The lens can be directed towards or away from the patient's eyes to enhance visualization and thus the examiner does not need to get too close to the patient and the scope of view is wider. The benefit of this study was that as far as the examiner knew, there had never been a study regarding the characteristics of ocular fundus in brain infection. Meanwhile, the results were recorded and can be played back repeatedly, allowing doctor-patient thorough discussion. However, the recorded results are strongly influenced by the examiner's ability, and thus became a weakness in this study.

Conclusion

Although CNS infection can cause an increase in ICP, papilledema is not always present. High opening pressure was found in the atrophic papillary group but the highest mortality was found in the normal fundus group. Nevertheless, further research is still needed with a larger sample. The availability of indirect funduscopy will facilitate easier and more frequent ocular fundus examination in brain infection patients.

References

1. Imran D, Estiasari R, Maharani K, Sucipto, Lestari DC, Yunus RE, et al. Presentation, etiology, and outcome of brain infections in an Indonesian hospital: A cohort study. *Neurol Clin Pract* [Internet]. Oktober 2018;8(5):379–88. <https://pubmed.ncbi.nlm.nih.gov/30564491>
2. Imran D, Satiti S, Sugianto P, Estiasari R, Maharani K, Pangeran D, et al. Barriers to diagnosis and management of CNS infections in Indonesia. *Neurology* [Internet]. 8 Januari 2019;92(2):104 LP –106. [.http://n.neurology.org/content/92/2/104.abstract](http://n.neurology.org/content/92/2/104.abstract)
3. Pachapure DS, B S DM, T Achar DM. Occurrence of Ocular Fundal Changes in Cases of Infective Meningitis and Meningoencephalitis in Our Hospital. *IOSR J Dent Med Sci*. 2014;13(1):54–9.
4. Sachdeva V, Vasseneix C, Hage R, Bidot S, Clough LC, Wright DW, et al. Optic nerve head edema among patients presenting to the emergency department. *Neurology*. 2018;90(5):e373–9.
5. American Academy of Ophthalmology. Selected Systemic Conditions With Neuro-Ophthalmic Signs. In: M. Tariq Bhatti, editor. *Neuro-ophthalmology*. 5 ed. San Francisco: American Academy of Ophthalmology; hal. 313.
6. Gu J, Xiao H, Wu F, Ge Y, Ma J, Sun W. Prognostic factors of tuberculous meningitis: a single-center study. *Int J Clin Exp Med* [Internet]. 15 Maret 2015;8(3):4487–93. <https://pubmed.ncbi.nlm.nih.gov/26064373>
7. Verma R, Sarkar S, Garg RK, Malhotra HS, Sharma PK, Saxena S. Ophthalmological manifestation in patients of tuberculous meningitis. *Qjm*. 2019;112(6):409–19.
8. Chan JW. Papilledema. In: *Optic Nerve Disorders*. Lexington: Springer US; 2007. hal. 62.
9. Grant T, Liu, Volpe NJ, Galetta SL. Optic disc swelling: papilledema and other causes. In: Russell Gabbedy, editor. *Neuro-Ophthalmology: Diagnosis and Management*. Second. Philadelphia: Elsevier; 2010. hal. 199.
10. Park Y-H, Nam H-W. Clinical features and treatment of ocular toxoplasmosis. *Korean J Parasitol* [Internet]. 2013/08/30. Agustus 2013;51(4):393–9. <https://pubmed.ncbi.nlm.nih.gov/24039281>