



## ACQUIRED PTOSIS IN PATIENT WITH SUSPECT MENINGIOMATOSIS

Moch. Fahmi\*, Nella Lusti Widhianingsih

\*Correspondence: fahmimochammad3@gmail.com

Department of Neurology, General Hospital of Jombang Regency, Jombang, Indonesia

### Article History:

Received: September 5, 2023

Accepted: October 31, 2023

Published: July 1, 2024

### Cite this as:

Fahmi M, Widhianingsih NL.  
Acquired Ptosis in Patient with  
Suspect Meningiomatosis. *Magna  
Neurologica*. 2(2) July 2024: 44-  
48.  
10.20961/magnaneurologica.v2i1  
.893

### ABSTRACT

**Background:** Ptosis is abnormally low positioned upper eyelid. It can be classified as congenital and acquired. Meningiomas are mostly benign tumors originating from meningeothelial (arachnoid) cells (MECs). A subset of meningioma patients bears two or more spatially separated synchronous or metachronous tumors termed "Multiple Meningiomas" (MM) or meningiomatosis.

**Case:** A 51-year-old female complained the dizziness was associated with nausea and emetic episodes. She reported any blurred vision and woke up with the dropped eyelid. Prior to this she had double vision and light headedness that she had 3 months before. The ophthalmic examination presented partial left ptosis and the patient's left eye was shifted towards the lateral edge at rest. CT scan with contrast presented multiple solid masses, extra axial, homogeneous, strong contrast enhancement with calvaria hyperostosis and perifocal edema in the left frontal region and left temporoparietal region.

**Discussion:** Ptosis in the left eye and exotropia is consistent with a left oculomotor nerve palsy. CT scan with contrast confirmed multiple solid masses leaning towards meningiomatosis. In this case, patient-acquired ptosis could be caused by direct oculomotor compression of the frontal lobe tumor, the tumor site being close to the superior orbital fissure.

**Conclusion:** Stemming from third cranial nerve dysfunction, multiple solid masses in the left frontal region indicate meningiomatosis. Acquired ptosis may result from direct compression of the oculomotor nerve by the frontal lobe tumor. While surgery is the primary treatment for meningiomas, corticosteroids may be considered in acute conditions to alleviate perifocal edema.

**Keywords:** meningioma, meningiomatosis, ptosis



This is an open access article distributed under the terms of the Creative Commons Attribution-4.0 International License

## Introduction

Ptosis is abnormally low positioned upper eyelid, also called blepharoptosis, which can decrease or even occlude the vision completely. It may be congenital or acquired in origin.<sup>1</sup> According to the etiologic, it can be further classified as myogenic, aponeurotic, neurogenic, neuromuscular, mechanical, traumatic, and pseudoptosis. Third nerve palsy and Horner's syndrome are the important causes of neurogenic ptosis. Third nerve palsy can result from vascular/inflammatory /neurotoxic or compressive etiology. It presents with ptosis, extraocular muscle involvement

sparing the lateral rectus and superior oblique, down and out eyeball and with or without pupillary involvement (Mydriasis).<sup>2</sup>

Ptosis can be an early sign of a life-threatening disease. Early diagnosis and proper evaluation are the important factors aiding treatment of this condition which can improve the quality of life of the people affected. Among acquired cases, aponeurotic ptosis is the most common type which usually presents in late adulthood. Marked unilateral ptosis with ocular deviation down and out are signs of a 3rd cranial nerve palsy. If associated with severe sudden onset of unilateral headache this can be due to a intracranial

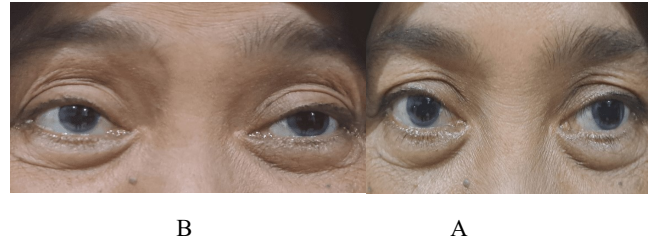aneurysm (dilated artery). Enough data is not available yet, about the incidence of ptosis caused by brain tumor.<sup>3,19</sup> Meningiomas are mostly benign tumors originating from meningotheial (arachnoid) cells (MECs), which make up 37,6% of all primary CNS tumors. Meningioma has an overall incidence of 8.3 per 100,000 persons during the period 2010–2014, which has increased over the past decade from a rate of 4.52 during the period 1998–2002. Meningiomas are more common in females and the incidence rate increases with age, increasing from 0.14 per 100,000 in children 0–19 years to 37.75 per 100,000 in the 75–84 year age<sup>4,12</sup>

A subset of meningioma patients bear two or more spatially separated synchronous or metachronous tumors termed “multiple meningiomas” (MM) or meningiomatosis, reported to occur in only 1%–10% of patients, though recent data indicate higher incidence. Meningiomatosis constitute a distinct clinical entity, with unique etiologists including sporadic, familial, and radiation-induced, and pose special management challenges. Meningiomatosis are often asymptomatic, probably because the majority are small and a significant proportion are induced by radiation. Approximately two-thirds of patients with multiple meningiomas require therapy, but only one-third of all meningiomas need active treatment.<sup>5,13</sup>

## Case Report

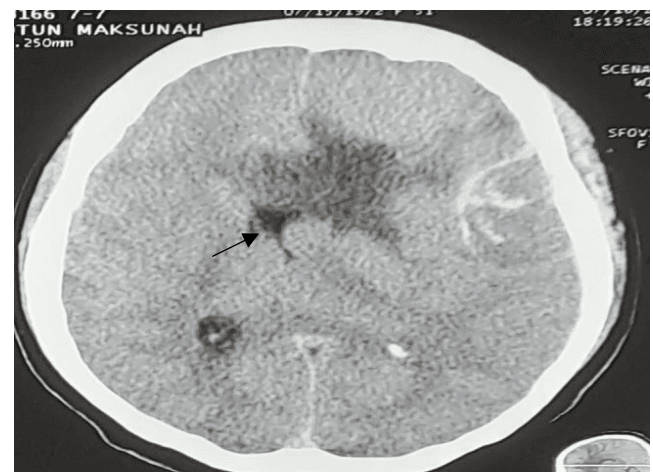A 51-year-old female presented to the emergency room complaining of having suffered, for an entire day, from the dizziness that she had experienced since waking up that morning. The complaint was associated with the light headedness, nausea and emetic episodes. She reported any blurred vision and woke up with the dropped eyelid she had felt in her left eye since that morning. Prior to this she had double vision and light headedness that she had 3 months before. She was without fever or seizure; she did not complain of weak limbs or slurred speech. History of previous illness such as diabetes, stroke, and high blood pressure was denied.

On examination the patient’s Glasgow Coma Scale score was 15 and she had a normal vital sign. The cranial nerve examination revealed a slight right VII and XII nerve central paresis type which is accompanied by slight hemiparesis in the right limb on motoric examination. The ophthalmic examination showed normal visual acuity and isochoric, normally reactive pupils. The patient had partial left ptosis, and although there were no apparent limitations in eye movements, the left eye was observed to be deviated towards the lateral edge at rest (Figure 1). This observation indicates a potential issue with eye muscle coordination or alignment.

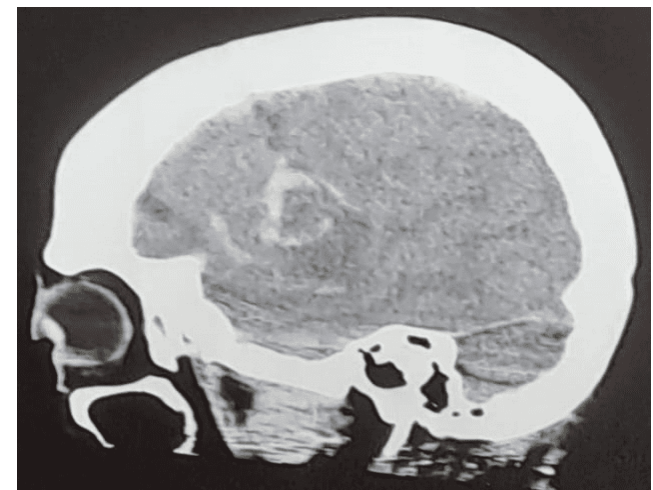


**Figure 1.** Patient’s Clinical Condition (A) Partial left Ptosis, (B) left eye displacement outward (exotropia)

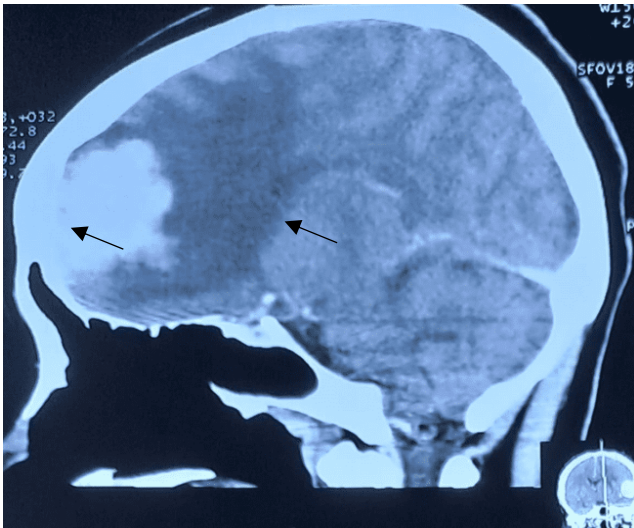
The cerebral CT scan showed a voluminous intracranial mass, of a left frontal extra-axial seat, well limited, widely in contact with the cranial vault, of a heterogeneous density associated to a perilesional oedema and a large mass effect on the midline. The patient was observed in the medical ward and evaluated on a CT scan with contrast. CT scan with contrast presented multiple solid masses, extra axial, homogeneous, strong contrast enhancement with calvaria hyperostosis and perifocal edema in the left frontal region, size +/- 4 cm, and left temporoparietal region, size +/- 4.3 cm, accompanied with midline shift to the right +/- 1.7 cm (see Figure 2). There were no abnormalities in Sulcus and gyrus, ventricular system and cysterna, pons and cerebellum. The Orbita, mastoid, and paranasal sinuses right and left were normal.



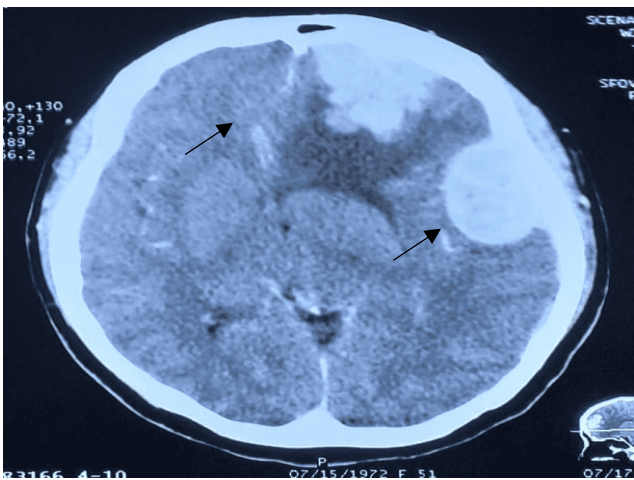
**A**



**B**



C



D

**Figure 2.** CT scan A. Plain CT Scan coronal image showing a heterogeneous density associated to a perilesional oedema and a large mass effect on the midline (black arrow), B. Plain CT Scan sagittal image, C. CT Scan with contrast coronal image presented multiple solid masses, extra axial, homogeneous, strong contrast enhancement (black arrow), D. CT Scan with contrast sagittal image showing solid mass with calvaria hyperostosis and perifocal edema in the frontal region (black arrow)

## Discussion

The patient complained the dizziness with nausea and emetic episodes, in association with ptosis in her left eye and displacement outward (exotropia) is consistent with a left oculomotor nerve palsy. Although we were not able to observe any limitation in ocular movements, this does not exclude III nerve palsy. The patient's oculomotor nerve palsy, along with contralateral facial and hypoglossal nerve palsy, indicates an intracranial process that needs evaluation. Ptosis in cases of cerebral ischemic or hemorrhagic stroke, trauma, or tumor, without brainstem or oculo-

sympathetic involvement, is termed cerebral ptosis. This eyelid dysfunction can occur with hemispheric involvement on either side.<sup>20</sup>

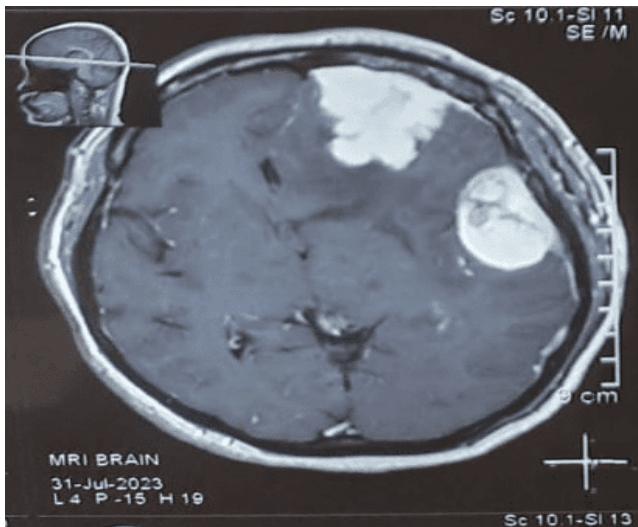
An urgent CT scan of the brain was done and showed space-occupying lesions with perilesional oedema in left cerebral hemisphere. Confirmed in the absence of fever, the lesion is more likely to be a tumor than an abscess. Tumor may increase intracranial pressure and cause symptoms such as headaches or focal neurological deficits either directly, due to their nature as space-occupying lesions, or indirectly, by causing peritumoral vasogenic cerebral edema. Presenting symptoms vary with location, but headaches or seizures are common, as are subacutely progressive neurological deficits. Hemispheric tumors may present with hemiparesis or hemisensory loss, while skull base lesions may present with vision loss or dysfunction of other cranial nerves.<sup>6</sup> In this case the brain tumors cause symptoms similar to those experienced by patient.

CT scan with contrast confirmed multiple solid masses, extra axial, homogeneous, strong contrast enhancement with calvaria hyperostosis and perifocal edema in the left frontal region leaning towards meningiomatosis. Meningiomatosis is the presence of two separate meningiomas simultaneously or two meningiomas in different regions without association with neurofibromatosis type 2. Meningiomatosis is a rare entity encompassing 2% of all meningiomas cases and is more frequent in women. Meningiomas are the most common primary central nervous system (CNS) tumors. They are usually benign, slow growing neoplasms that are thought to arise from meningeothelial (arachnoid) cells (MECs).<sup>4,15</sup> This is consistent with the patient's complaints of diplopia and light headedness in the last two months which indicates a chronic process.

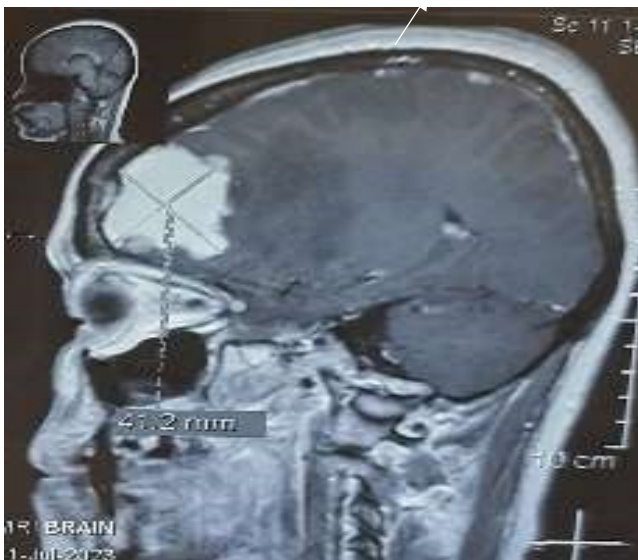Third cranial nerve dysfunction, oculomotor nerve palsy (ONP), can result from lesions anywhere along the nerve between the midbrain and the orbit. This can include the oculomotor nucleus, the fascicles in the midbrain tegmentum and the spaces it passes through, including the subarachnoid space, the cavernous sinus, and the superior orbital fissure. Third cranial nerve is a motor nerve and supplies all extraocular muscles except lateral rectus and superior oblique in addition also supplies sphincter pupillae and ciliary muscles. The paresis or paralysis of one or more of these muscles due to 3rd cranial nerve palsy leads to ocular motility defects, ptosis, anisocoria and loss of accommodation.<sup>7,16</sup> In this case, patient-acquired ptosis could be caused by direct oculomotor compression from the frontal lobe tumor or its surrounding swollen tissue, as the tumor is near the superior orbital fissure affecting oculomotor nerves. Another tumor in the left temporoparietal lobe caused mild right limb disturbance and mild paresis of the right

VII and XII nerves, as noted in the patient's neurological examination.

While in the hospital ward, the patient was given symptomatic therapy to treat dizziness and vomiting. Dexamethasone was given to reduce the effects of perifocal edema caused by meningioma. The patient received a dose of dexamethasone 3 times 5 mg a day, and showed clinical improvement within 3 days of treatment. Dexamethasone is the corticosteroid most commonly used for the management of vasogenic edema and increased intracranial pressure in patients with brain tumor.<sup>8</sup> Several practice guidelines discuss dosing schedule of dexamethasone in specific indications, 4 mg twice a day or four times a day for mild to moderate neurologic symptom.<sup>9</sup>



A



B

**Figure 3.** MRI A. Sagittal image showing nodular meningioma on the frontal lobe near with orbita, B. Coronal image showing multiple meningioma with dura tail (white arrow).

Regarding further treatment, the patient was referred to a neurosurgeon. In the neurosurgery department, an MRI examination was performed. A provisional diagnosis of meningioma is typically made by neuroimaging, mostly magnetic resonance imaging. Such provisional diagnoses may be made incidentally.<sup>18</sup> The MRI results showed nodular meningioma on the left frontal, temporal, and enplaque meningioma on the left parietal (Figure 3). View of the dural tail, defined as enhancement of the dura infiltrating away from the lesion and described in up to 72 % of cases in one study. In this circumstance, the presence of a dural tail may be useful to distinguish meningiomas from other potential aetiologies; for example, in distinguishing meningioma from schwannoma.<sup>10</sup>

The management options include surgical resection, radiation therapy, and stereotactic radiosurgery, with surgery being the treatment of choice.<sup>17</sup> Surgery is the first choice if the lesion is symptomatic, more than 3 cm and in a location that can be reached by surgery. The prognosis is usually very good because of its benign nature. The prognosis is no different from solitary benign meningioma. Because tumors grow very slowly, small tumors may be followed up every 6 months then 1 year if asymptomatic. However, we now understand that a significant proportion of meningiomas (20–30%) are clinically aggressive and have a proclivity to recur with significant morbidity and even mortality. While there is no accepted definition of “poor outcome” in meningioma, aggressive subtypes often have a 5-year progression free survival (PFS) probability less than 50%.<sup>11,14</sup>

## Conclusion

Ptosis accompanied by exotropia can be caused by third cranial nerve dysfunction. Oculomotor nerve palsy (ONP) can result from lesions anywhere along the nerve between the midbrain and the orbit. Multiple solid masses, extra axial, homogeneous, strong contrast enhancement with calvaria hyperostosis and perifocal edema in the left frontal region leaning towards meningiomatosis. In this case, patient-acquired ptosis could be caused by direct oculomotor compression of the frontal lobe tumor or the swollen tissue around the tumor, the tumor site being close to the superior orbital fissure that provides access to oculomotor nerves. Surgery is the main stay of treatment for symptomatic meningioma, but for acute condition corticosteroid administration to reduce perifocal edema may be considered.

## References

1. Koka K, Patel BC. Ptosis Correction. Retrieved on Jul 20, 2023. Available from: <https://www.ncbi.nlm.nih.gov/books/NBK539828/>
2. Pauly M, Sruthi R. Ptosis: Evaluation and management. *Kerala Journal of Ophthalmology*; 2019. 31(1):11-6. Retrieved on Jul 20, 2023. Available from: <https://www.researchgate.net/>
3. Shahzad B, Siccardi MA. Ptosis. Retrieved on Jul 20, 2023. Available from: <https://www.ncbi.nlm.nih.gov/books/NBK546705/>
4. Ogaswara C, Philbrick BD, Adamson DC. Review Meningioma: A Review of Epidemiology, Pathology, Diagnosis, Treatment, and Future Directions. *Biomedicines*; 2021. 309(9):1-23. DOI: 10.3390/biomedicines9030319
5. Fahlstrom A, Dwivedi S, Drummond K. Multiple meningiomas: Epidemiology, management, and outcomes. *Neuro-Oncology Advances*; 2023. 5(S1): i35–i48. DOI: 10.1093/noon/vdac108
6. Fogh SE, Johnson DR, Barker FG, Brastianos PK, Clarke DL, Kaufmann TJ, et al. Cased-Based Review: Meningioma. *Neurooncol Pract*; 2016. 3(2): 120–134. DOI: 10.1093/nop/npv013
7. Khaleefah MM, Narayanan S, Aldallal HA, Jones CM, Friedland RP, Palade AE, et al. Review Meningioma: A Review of Epidemiology, Pathology, Diagnosis, Treatment, and Future Directions. *Oncology Letters*; 2020. 285(20):1-8. DOI: 10.3892/ol.2020.12088
8. Kostaras X, Cusano F, Kline GA, Roa W, Easaw J. use of dexamethasone in patients with high-grade glioma: a clinical practice guideline. *Curr Oncol*; 2014. 21(3): e493-e503. DOI: 10.3747/co.21.1769
9. Jessurun CA, Hulsbergen AF, Cho LD, Aglio LS, Tewarie RD, Broekman ML. Evidence-Based Dexamethasone Dosing in Malignant Brain Tumors: What Do We Really Know?. *J Neurooncol*; 2019. 144 (2): 249-264. DOI: 10.1007/s11060-019-03238-4
10. Watts J, Box G, Galvin A, Brotchie P, Trost N, Sutherland T. Magnetic resonance imaging of meningiomas: a pictorial review. *Insight Imaging*; 2014. 5:113–122. DOI: 10.1007/s13244-013-0302-4
11. Chaurasia B, Hossain M, Barua KK, Rokib RI, Biswas P, Sardar M, et al. Meningiomatosis in non-neurofibromatosis patient: how we dealt with 8 tumors. *J Neurol Stroke*; 2018. 8(6):307–310. DOI: 10.15406/jnsk.2018.08.00335
12. Buerki RA, Horbinski CM, Kruser T, Horowitz PM, James CD, Lukas RV. An overview of meningiomas. *Future Oncol*; 2018. 14(21):2161-2177. DOI: 10.2217/fon-2018-0006
13. Tsermoulas G, Turel MK, Wilcox JT, Shultz D, Farb R, Zadeh G, Bernstein M. Management of multiple meningiomas. *Journal Of Neurosurgery*; 2017. 128(5):1403-1409. DOI: 10.3171/2017.2.JNS162608
14. Wang JZ, Nassiri F, Landry AP, Patil V, Liu J, Aldape K, Gao A, Zadeh G. The multiomic landscape of meningiomas: a review and update. 2023;161: 405-414. DOI: 10.1007/s11060-023-04253-2
15. Huntoon K, Toland AMS, Dahiya S. Meningioma: A Review of Clinicopathological and Molecular Aspects. *Front Oncol*; 2020. 10: 579-599. DOI: 10.3389/fonc.2020.579599
16. Ali Q, Minu S, Asif S, Alka J. Management of Third Nerve Palsy- An Overview. *EyeQuest*; 2021. 46(2): 82-84. DOI: 10.4103/2222-8888.358881
17. Sharma S, Sharma P, Kumar A. Diffuse Meningiomatosis without Neurofibromatosis: A Rare Diagnosis with Atypical Presentation. *Indian J Radiol Imaging*; 2021. 31 (3):768-771. DOI: 10.1055/s-0041-1736394
18. Goldbrunner R, Stavrinou P, Jenkinson MD, Sahn F, Mawrin C, Weber DC, et al. EANO guideline on the diagnosis and management of meningiomas. *Neuro Oncol*; 2021. 23(11): 1821-1834. DOI: 10.1093/neuonc/noab150
19. Ogun O. Red flags in neuro-ophthalmology. *Community Eye Health Journal*; 2016. 29 (96):64-65. Retrieved on Jul 20, 2023. Available from: <https://cehjournal.org/articles/red-flags-in-neuro-ophthalmology?>
20. Vegda M, Panda S, Tiwari S, Shukla K, Pamnani J, Bhaskar S. Cerebral Ptosis: A Revisit. *Neurol India*; 2022. 70 (3):1166-1169. DOI: 10.4103/0028-3886.349612