



CASE REPORT

OPEN ACCESS

# PATIENT WITH FOREIGN ACCENT SYNDROME IN POST INFARCT THROMBOTIC STROKE: A CASE REPORT

Firstiafina Tiffany\*, Ira Ristinawati, Shafira Nur Hanifa

\*Correspondence: [firstiafina.tiffany@gmail.com](mailto:firstiafina.tiffany@gmail.com)

Department of Neurology, Faculty of Medicine, Universitas Sebelas Maret, Surakarta, Indonesia

**Article History:**

Received: September 5, 2023

Accepted: October 24, 2023

Published: January 1, 2024

**Cite this as:**

Tiffany F, Ristinawati I, Hanifa SN. Patient with Foreign Accent Syndrome in Post Infarct Thrombotic Stroke: A Case Report. *Magna Neurologica*. 2(1) January 2024: 26-33. 10.20961/magnaneurologica.v2i1.894

**ABSTRACT**

**Background:** Stroke is the second leading cause of death in the world and is the leading cause of disability worldwide. One of the disabilities is language disorder. Foreign Accent Syndrome (FAS) is a clinical condition associated with a noticeable change of accent, that could affect verbal communication and social interaction skills. By identifying this case earlier, we hope that the patient's activity daily living is less disrupted.

**Case:** A 54-year-old woman presented with right limb weakness and tingling, along with a change in speech accent from Javanese to Madurese, despite no prior exposure to Madurese. Neurobehavioral examination revealed language and memory disturbances, and MRI showed cerebral infarction in the bilateral hippocampi, small vessel ischemia in the bilateral frontal lobes, and corona radiata.

**Discussion:** The accent change, known as FAS that was experienced by the patients are thought to be due to neurological causes, which was stroke. In a study using a lesion network mapping approach concluded that the lesion causing accent disorder was located within a single network in the bilateral frontal lobe. In line with the existing theory, the MRI results in this patient showed ischemia in the blood vessels of the bilateral frontal lobes.

**Conclusion:** Clinical symptoms related to stroke depending on the location of the lesion. The accent change in this patient, known as Foreign Accent Syndrome (FAS), is believed to be caused by stroke affecting the bilateral frontal lobes. Early recognition of FAS can help reduce disruptions in communication and social interactions.

**Keywords:** foreign accent syndrome, neurobehavior, stroke infarction



This is an open access article distributed under the terms of the Creative Commons Attribution-4.0 International License

## Introduction

A stroke is a neurological deficit caused by acute focal injury to the central nervous system due to vascular causes, especially cerebral infarction. There are two types of stroke: hemorrhagic stroke and ischemic stroke.<sup>1</sup> The Trial Organization 10172 in Acute Stroke Treatment (TOAST) categorizes ischemic strokes into some number of subgroups, including cardioembolism, small vessel occlusion, major artery atherosclerosis, and strokes with unknown causes. In 2019, stroke being the second-leading cause of death globally, count for 11.3% of all cause of deaths, and the third-leading cause of morbidity and mortality. Disability-adjusted life years (DALYs) increased by 32% and stroke mortality by 43% between 1990 and 2019.<sup>2</sup>

One of the disabilities that was caused by the stroke is language disorder.<sup>3</sup> Language disorder can manifest as fluently disorder, language comprehension disorder, repetition, item naming, reading, or writing.<sup>4</sup> 25% to 40% of stroke survivors experience language disorder.<sup>3</sup> Language disorder associated with more severe stroke, which makes post-stroke language disorder a significant disability for patients and a risk factor for high mortality. Additionally, people with language disorder are more likely to have depression and lower chance of going back to work, all of which have a detrimental impact on their quality of life.<sup>5</sup>

Good sentence structure and understandable accent are crucial elements of language, as these two factors could affect the sentence's comprehension that would

accepted by the interlocutors.<sup>6</sup> Variations in pitch, pressure, and rhythm in accented speech; articulation; slow production of speech can give words emotional meaning, in which this components may be disrupted in patient with Foreign Accent Syndrom (FAS).<sup>7</sup> FAS is a clinical condition associated with a noticeable change of accent. Foreign accent impression in patient with neurogenic FAS was resulted from a misinterpretation by the listener.<sup>8</sup> This condition being

a major concern for the patient, because it could affect their verbal communication and social interaction skill.<sup>9</sup> In fact, FAS in patient with the history of stroke could seriously impair their verbal communication and social interaction skill.<sup>10</sup> While studies on FAS after stroke are relatively scarce, those that are accessible focus more on language disorders in post-stroke patients.

## Case Report

A 54-year-old woman complained of tingling and weakness in her right limbs as well as a change in her language accent when she visited Dr. Moewardi at the RSUD Neurology Clinic. Before the stroke attack, the patient was still able to move, talk, and carry out daily activities. The patient's right limb began to weaken 4 years after the stroke attack. The patient had a Javanese accent when speaking before having a stroke. One year later, the patient, who had never lived in Madurese or learned the language before the stroke, began speaking with a Madurese accent. The patient has reported experiencing tingling for a year following their stroke, although these concerns have started to go better. The patient had a history of hypertension and consistently took medication before the stroke attack. The patient denied having undergone surgery or experienced any prior trauma.

On the physical examination, the consciousness level was E4V5M6 and the blood pressure was 152/106 mmHg. On the physical examination, right-limb weakness was found. The patient speaks fluently; there is no repetitiveness, they can name objects, and he understands phrases well. However, patients may struggle to communicate what they want to say. Additionally, a motor assessment revealed no paresis, paralysis, or apraxia. The patient was determined to have issues in the language and memory domain during the neurobehavioral evaluation. A brain infarction in the hippocampal region and small vessel ischemia in the frontal lobe and corona radiata were both seen on magnetic resonance imaging (MRI) (Figure 1). Examination of electrolytes, electrocardiography, and blood sugar within normal bounds. Candesartan 1x8 mg, cilostazol 1x100 mg, piracetam 1x800 mg, and citicolin 1x500 mg were given to patients as part of their treatment.

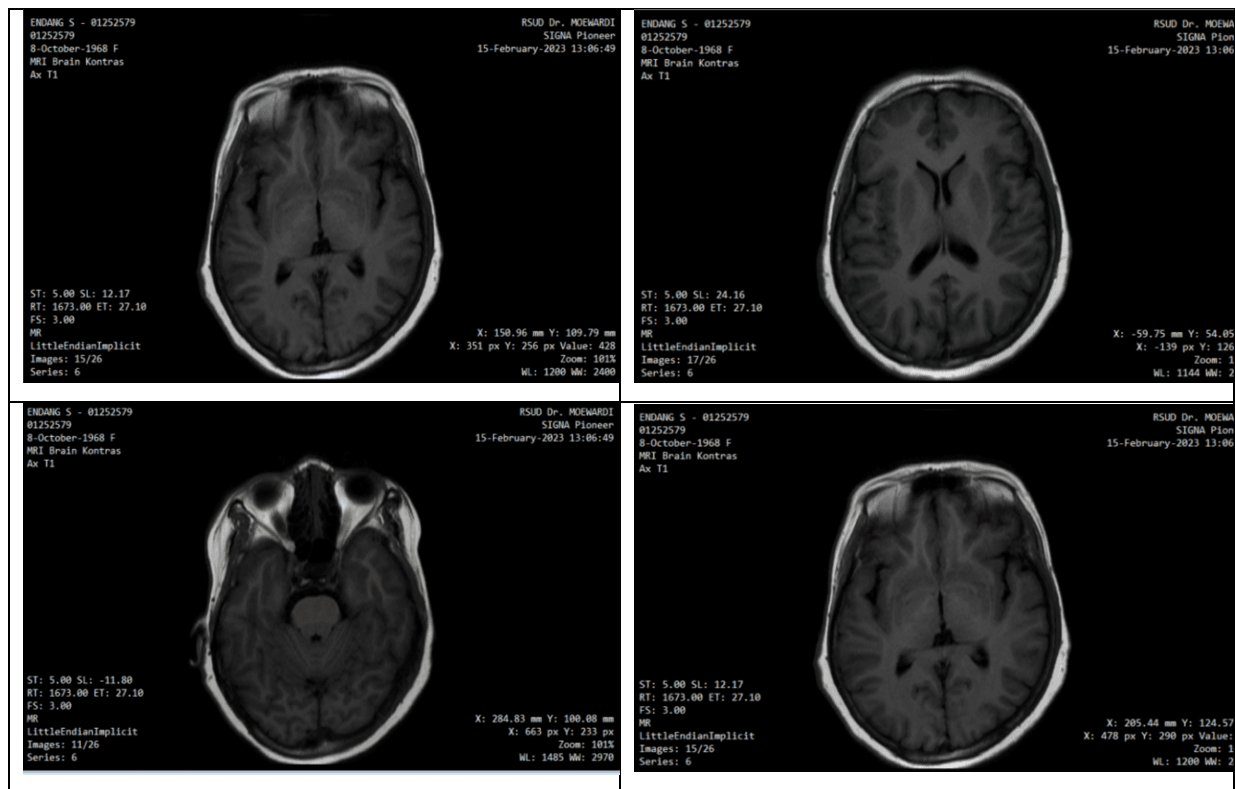


Figure 1. MRI on T1 slice of the patient

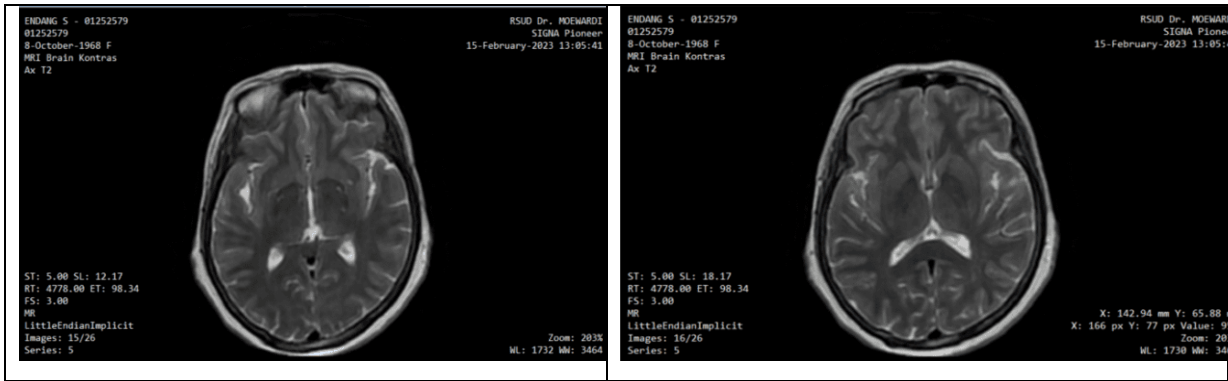


Figure 2. MRI on T2 slice of the patient

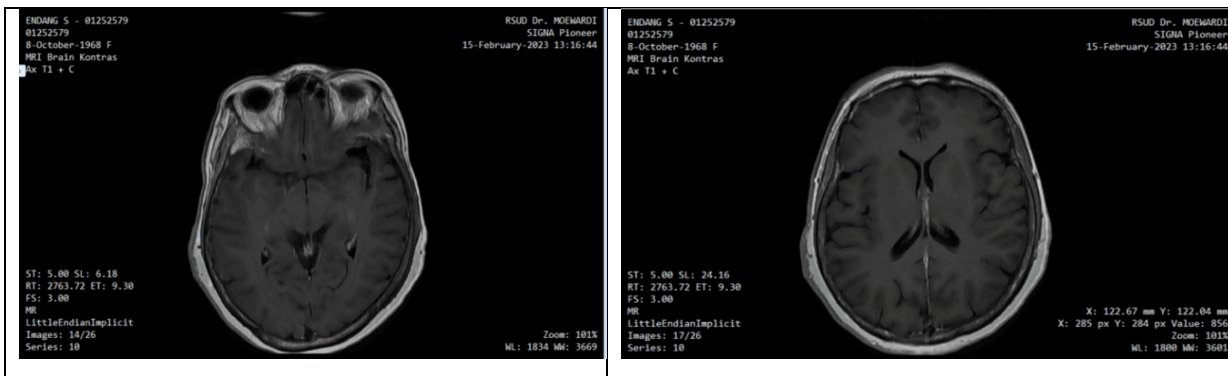


Figure 3. MRI on T1+C slice of the patient

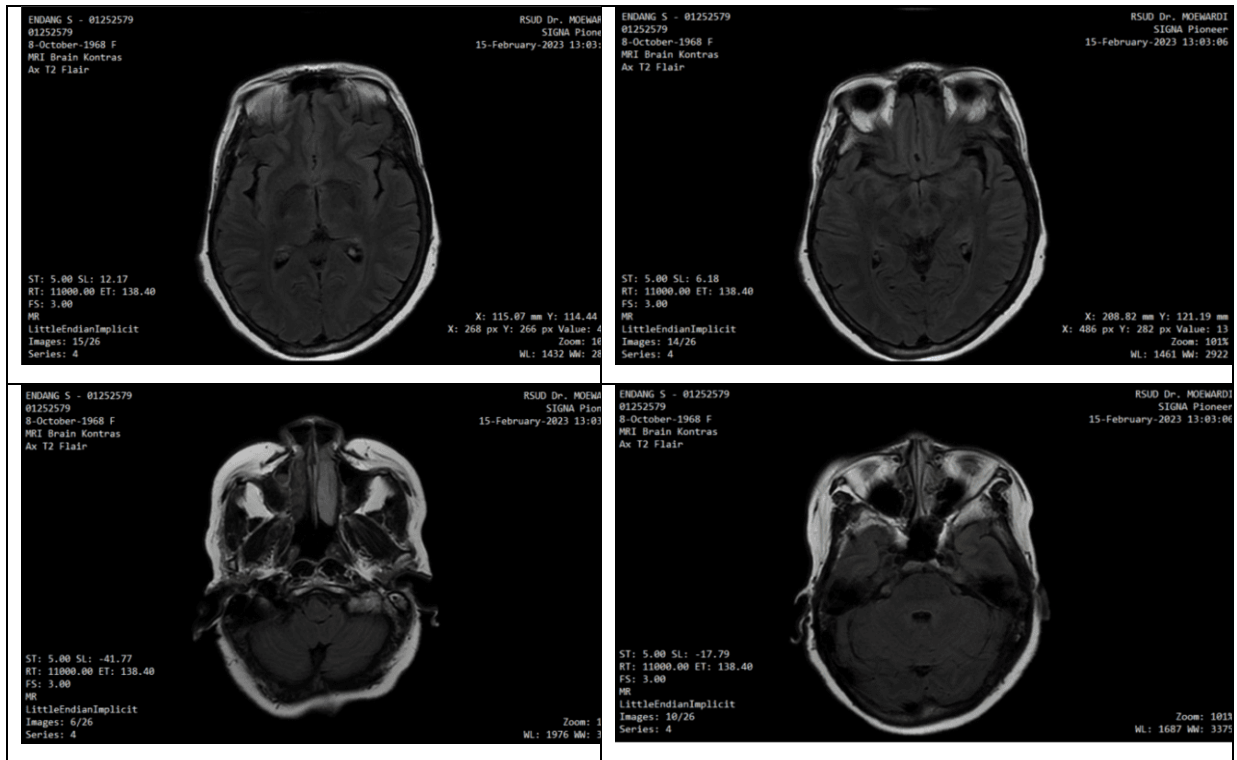


Figure 4. MRI on T2 FLAIR slice of the patient

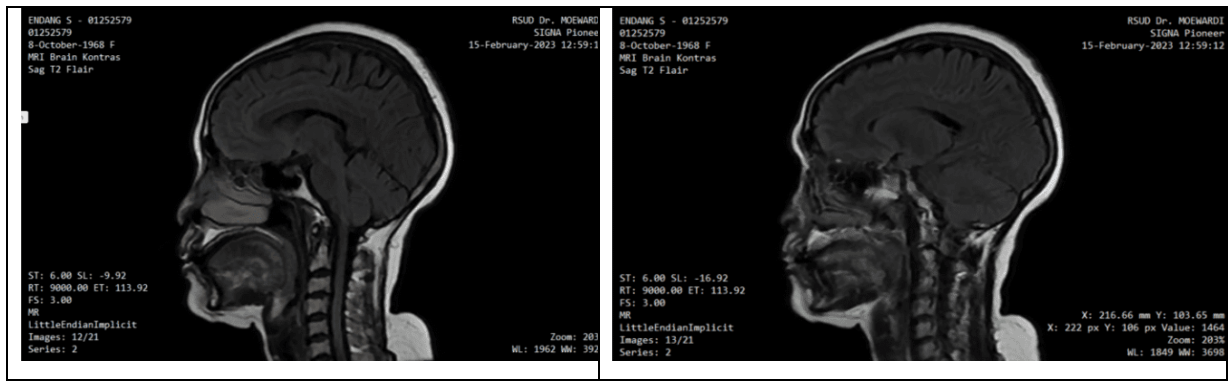


Figure 5. MRI on T2 FLAIR slice of the patient

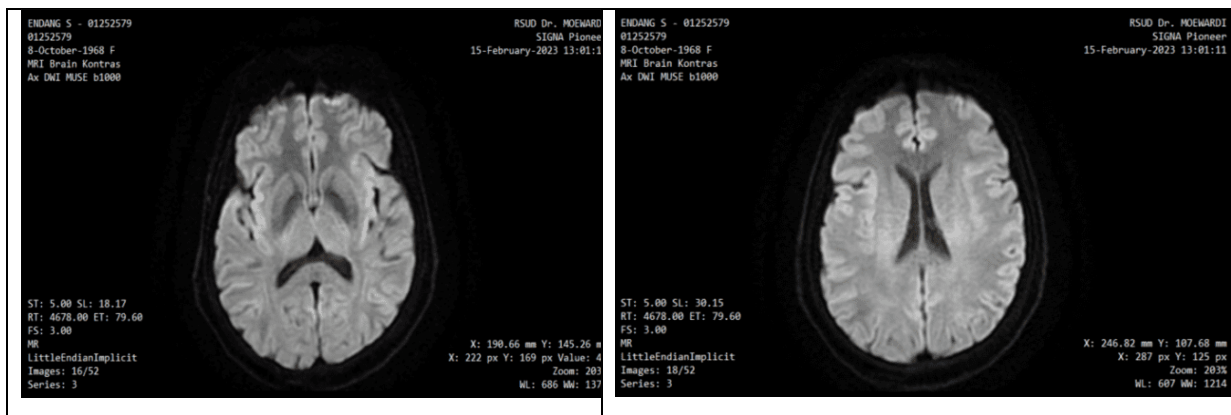


Figure 6. MRI on DWI slice of the patient



**Neurobehaviour Clinic**

**RSUD Dr. Moewardi**

**KSM/Neuroscience Laboratory**

Jl. Kolonel Sutarto 132 Solo

Telp 0271 634 634

**Neurobehaviour Examination Test Result**

|                   |           |                         |             |
|-------------------|-----------|-------------------------|-------------|
| <b>Name</b>       | Ny. E     | <b>Examination Date</b> | 11 May 2023 |
| <b>Age</b>        | 55 y.o.   | <b>No RM</b>            | 01252xxx    |
| <b>Address</b>    | Sragen    |                         |             |
| <b>Occupation</b> | Housewife |                         |             |

|  |
|--|
| <b>Anamnesis</b>   |
| Patients complain that they occasionally still forget to put things away, but they claim that this is better than it was two years ago. According to the patient, accent language disorders like the Madurese continue to alter. History of strokes in 2019. |

| No | Test  | Score | Normal       | Description |
|----|---|-------|--------------|-------------|
| 1  | Global Cognition Function<br>1. MoCA-Ina  | 24    | ≥ 25.8       | less        |
| 2  | Atention<br>2.1. Forward Digit Span   | 8     | 5            | normal      |
| 3  | Language<br>3.1. Boston Naming Test<br>3.2. Verbal Fluency Test   | 11    | 13.84±1.23   | less        |
|    |   | 16    | 19.84±5.98   | normal      |
| 4  | Memory<br>4.1. Word List Memory Task<br>4.2. Word List Memory Recall<br>4.3 Word List Memory Recognition<br>4.4 Recall of Constructional Praxis | 18    | 19.84±5.98   | normal      |
|    |   | 6     | 8.05±1.66    | less        |
|    |   | 10    | 9.88±0.36    | normal      |
|    |   | 9     | 10.61±0.97   | less        |
| 5  | Executive Function<br>5.1. Trail Making Test B<br>5.2. Verbal Fluency   | 145   | 113.48±58.48 | normal      |
|    |   | 16    | 19.84±5.98   | normal      |
| 6  | Visuokonstruktion<br>6.1. Constructional Praxis   | 11    | 10.61±0.97   | normal      |
| 7  | Language Comprehension Test<br>7.1. Token Test  | 30    | >29          | normal      |
| 8  | Lawton IADL Score   | 8     | 8            | normal      |

|   |
|---|
| <b>Conclusion</b>   |
| The current neurobehavior examination found disturbances in the global cognition function domain, language subdomain and memory subdomain. Impressions towards Vascular Cognitive Impairment. |

**Figure 7.** Neurobehavior Examination Test

## Discussion

There are modifiable and non-modifiable risk factors for ischemic stroke. History of diabetes mellitus, coronary heart disease, history of hypertension, socioeconomic status, lifestyle, and history of alcohol use are lists of factors that could be modified. While age, gender, and race are risk factors that cannot be modified.<sup>11</sup> The most frequent risk factor affecting the incidence of stroke is hypertension, both in young-onset (age group less than 50 years) and in old-onset.<sup>1</sup> When the patient experiences hypertension, the increase in intraluminal pressure will eventually damage the endothelium. Blood and endothelium interact due to endothelial injury, resulting in systemic lesions and localized thrombus development.<sup>7</sup> The patient has hypertension, and according to the anamnesis, the patient consumes antihypertension that was given by the doctor regularly. However, when the patient went to the doctor and the blood pressure was measured, it was found that the patient's blood pressure was 152/105 mmHg, which was classified as type I hypertension. Clinical symptoms that were found in stroke patients differ according to the location of the lesion.

In this case, the patient experienced right limb weakness following a stroke 4 years prior, along with speech difficulties. One year after the incident, patient was able to talk clearly. The patient, who had previously spoken with a Javanese accent, suddenly switched to a Madurese accent, which the patient had never learnt before.

FAS is a relatively rare motor speech disorder characterized by speech errors which are perceived as a foreign accent by members of the same language community as the patient.<sup>12</sup> FAS disorders or accent change are typically caused by neurological or biological factors, although it can also be caused by psychological factors (such as functional or psychogenic disorders).<sup>8</sup> The most common etiology of FAS is stroke, followed by head trauma, metastatic brain tumor, multiple sclerosis, progressive degenerative brain disease, including primary progressive aphasia, learning disorders and psychogenic disorders, in the intermediate period ranging from about three weeks to three months post-onset (Figure 2).<sup>12</sup> More than 70% of cases are caused by neurological factor, resulting from stroke, and the majority of these conditions are related to supratentorial lesions in the right hemisphere (Figure 3).<sup>9</sup>

Neurogenic FAS commonly related to combination of segmental and suprasegmental pronunciation characteristics which can be deviate from what is expected on the basis of the speech community to which

the speaker belongs. At segmental level, the problem related to the phonetic distortions and phonemic paraphasia.<sup>13</sup> At the suprasegmental level, neurogenic FAS often noted to have change in speech rhythm which is described as slow or problem with stress placement, different, isosyllabic, staccato, scanning or syllable-timed (Figure 4).<sup>14</sup> The morphology of the lesion remaining the same, neurobehavioral symptoms in the earlier period (the acute phase; until approximately 3 weeks post-stroke) are often more severe than the lesion would suggest (due to the additional effect of diaschisis affecting ipsi- or contralateral brain areas, mass effect and peri-lesional damage (penumbra) (Figure 5). The effects of damage also depend on the affected brain area and they may become less severe in the later period (the chronic phase; after approximately 3 months post-stroke) due to the opposite effect of functional compensation resulting from spontaneous recovery or therapy. Neurocognitive and neurolinguistic disorders presumably mirror the effect of the lesion most faithfully in an intermediate period called the lesion phase of the stroke (Figure 6).<sup>12</sup>

Preservation of speech intelligibility could be the pathognomonic feature to differentiate the organic type from the functional type. It was shown from the case report presenting two types of foreign accent syndrome, organic and functional type, the patient with the organic type has a score of 95.5 from speech intelligibility rating compared to the functional type with a score of 55.3.<sup>8</sup> In a study that used "lesion network mapping", it was discovered that the lesion responsible for accent disorder share common functional network located in the bilateral posterior region of the frontal lobe.<sup>7</sup> Several areas in the frontal lobe that predominantly contribute to the emergence of accent disorders: bilateral middle portion of the precentral gyrus, the bilateral lower portion of the precentral gyrus extending to the insular cortex, and the supplementary motor area (SMA).<sup>7,12</sup> Medial part of the pre-central gyrus is a motor cortex area, which has a specific role in controlling larynx intrinsic muscle.<sup>7</sup>

Larynx was the phonation organ, which consist of two groups of muscle, namely intrinsic and extrinsic larynx muscle, that regulate the vocal folds. The intrinsic muscles control 2 dimensions of vocal-fold movement to modify the positioning and tension of the vocal folds. One dimension involves the opening (abduction) and closing (adduction) of the glottal space, while the other involves tensing and relaxing of the vocal folds for the purpose of altering vocal pitch (F0 variation) and vocal intensity. Control of vocal pitch, corresponding to the vocal fold eigenfrequencies, is achieved mainly by varying the stiffness and tension of the vocal folds through the activation of the intrinsic laryngeal muscles, especially the cricothyroid muscle.

The intrinsic muscles also increase vocal intensity, either elevating the subglottal pressure, which increases vibration amplitude, or increasing vocal fold adduction.<sup>7,13</sup> Other than that, this region play a role in vowel phonation and glottal stop (i.e., forced closure of the glottis in the absence of vocalizing).<sup>13</sup>

According to these characteristics, FAS characterized by altered normal pitch and intensity may be attributed to intrinsic laryngeal muscle dysfunction controlled by the medial pre-central gyrus.<sup>15</sup> The Rolandic operculum, which consists of the inferior pre-central gyrus and the post-central gyrus, is involved in lip and tongue movement.<sup>16</sup> The Rolandic operculum is an important area for intra- and inter-syllable coordination of complex articulation movements.<sup>17</sup> Supplementary Motor Area (SMA) located in the medial part of the frontal lobe anterior. Accent disorder could result from SMA lesions. Additionally, it is known that damage to the SMA, particularly the left portion, can result in SMA aphasia, a peculiar aphasia that is characterized by a lack of spontaneous speech initiation and well-maintained articulation when speech is began. SMA also regulates behavioral functions, internal driven activities, sequential activities, the process of learning new tasks, and cognitive processes in addition to language functions.<sup>17,18</sup> The patient's accent changes, from Javanese to Madurese, were made possible by interference in the bilateral frontal lobes, in accordance with the MRI findings, which showed the presence of ischemia of the small vessels in the patient's bilateral frontal lobes. The patient's MRI findings are consistent with those of the neurobehavioral test, which revealed an impairment on language domain.

Patient with a history of stroke could also have a cognitive impairment. In a study stated that the prevalence of cognitive defect in patient with a history of stroke between 11.6% and 56.3%. 38% of them were assessed to have a cognitive defect three months post stroke using MMSE scoring. Dominantly, the patients which have cognitive impairment had lesions in frontotemporal areas. Some of patients with cognitive impairment post stroke had a problem with arithmetics. Arithmetics requires intact short- and long-term memory functions, attention, and mental flexibility and is subserved by mainly parietal and pre-frontal cortex. Basal ganglia lesions, attested for, give rise to similar cognitive impairments as frontal lesions due to a network of fronto-subcortical loops. The basal ganglia are implicated in a wide variety of cognitive functions, including executive functions, attention, visual perception, sequential processing and learning—which were variably disrupted in—but also speech. These behavioural effects are demonstrated in vascular FAS cases with basal ganglia damage.<sup>13</sup>

FAS to disruption of the cortico-striato-pallidalthalamic pathway, consisting of many regions that cooperate in an integrated fashion to regulate many different cognitive functions.<sup>19</sup> Although many issues must be resolved, this circuit is clearly involved in various speech and language processes. Lesion in hippocampus presents as an anterograde amnesia, but is not always associated with retrograde amnesia, and old memories are often retained. Widespread damage to the medial aspect of the temporal lobe, such as the hippocampus and parahippocampal gyrus, impairs retrieval of old memories and results in severe backward amnesia.<sup>18,20</sup> According to the neurobehavioural test result, the patient having any disturbance in the global cognition function domain, especially the memory subdomain. In line with the MRI result, stated that the patient has an infarct in the hippocampal region and small vessel ischemia in the frontal lobe, which these areas responsible for memory function (Figure 7).

## Conclusion

Clinical symptoms related to stroke depending on the location of the lesion. In this case, the patient had speaking difficulties after a stroke. One year later, the patient started to talk clearly, but her speaking accent had changed. The existence of ischemia in the blood vessel of the frontal lobes bilateral, where these findings are congruent with the patient's MRI results, allowed for the shift in accent in this case. FAS are still infrequently recognized. In fact, FAS in post-stroke patients can seriously hinder verbal communication and social interaction.

## References

1. Stevano R, Margono JT, Sutanto A. Clinical Profile And Risk Factors Of Stroke: A Comparative Analytical Study Between Young And Old Onset. *Magna Neurol*; 2023 Jan. 1(1):13–6. Retrieved on Feb 21, 2023. Available from: <https://journal.uns.ac.id/magnaneurologica/article/view/470>
2. Widiasari V, Rahman FF, Ningrum V. The Incidence and Prevalence of Stroke by Cause in Indonesia Based on Global Burden of Disease Study 2019. In: *Proceedings of the 3rd International Conference on Cardiovascular Diseases (ICCVd 2021)*. Dordrecht: Atlantis Press International BV; 2023. 435–46. Retrieved on Feb 21, 2023. Available from: [https://www.atlantispress.com/doi/10.2991/978-94-6463-048-0\\_50](https://www.atlantispress.com/doi/10.2991/978-94-6463-048-0_50)

3. Khedr, E.M., Abbass, M.A., Soliman, R.K. et al. A hospital-based study of post-stroke aphasia: frequency, risk factors, and topographic representation. *Egypt J Neurol Psychiatry Neurosurg*; 2020. 56(2):1-7. Retrieved on Feb 21, 2023. Available from: <https://doi.org/10.1186/s41983-019-0128-1>
4. Febryanto D, Retnaningsih, Handayani F. Assessment Of Afasia in Stroke Patients: Case Study. *J Nurs Pract*; 2020 Apr. 3(2):210–9. Retrieved on Feb 21, 2023. Available from: <https://thejnp.org/index.php/jnp/article/view/88>
5. Grönberg A, Henriksson I, Stenman M, Lindgren AG. Incidence of Aphasia in Ischemic Stroke. *Neuroepidemiology*; 2022. 56(3):174–82. Retrieved on Feb 21, 2023. Available from: <https://www.karger.com/Article/FullText/524206>
6. LaCroix AN, Blumenstein N, Houlihan C, Rogalsky C. The effects of prosody on sentence comprehension: evidence from a neurotypical control group and seven cases of chronic stroke. *Neurocase*; 2019 Jul. 25(3–4):106–17. Retrieved on Feb 21, 2023. Available from: <https://www.tandfonline.com/doi/full/10.1080/13554794.2019.1630447>
7. Higashiyama Y, Hamada T, Saito A, Morihara K, Okamoto M, Kimura K, et al. Neural mechanisms of foreign accent syndrome: Lesion and network analysis. *NeuroImage Clin*; 2021. 31:102760. Retrieved on Feb 21, 2023. Available from: <https://linkinghub.elsevier.com/retrieve/pii/S2213158221002047>
8. Barreto S dos S, Ortiz KZ. Speech in the foreign accent syndrome: differential diagnosis between organic and functional cases. *Dement Neuropsychol*. 2020 Sep. 14(3):329–32. Retrieved on Feb 21, 2023. Available from: [http://www.scielo.br/scielo.php?script=sci\\_arttext&pid=S198057642020000300329&tlng=en](http://www.scielo.br/scielo.php?script=sci_arttext&pid=S198057642020000300329&tlng=en)
9. Zhang Z. Mechanics of human voice production and control. *J Acoust Soc Am*; 2016 Oct. 140(4):2614–35. Retrieved on Feb 21, 2023. Available from: <https://pubs.aip.org/jasa/article/140/4/2614/920673/Mechanics-of-human-voice-production-and-control>
10. Alrabghi, L., Alnemari, R., Aloteebi, et al. Stroke types and management. *International Journal Of Community Medicine And Public Health*; 2018. 5(9), 3715–3719. Retrieved on Feb 21, 2023. Available from [doi.org/10.18203/23946040.ijcmph20183439](https://doi.org/10.18203/23946040.ijcmph20183439)
11. Rianawati, S. B., Aurora, H., & Nugrahanitya, Y. Correlation Between Blood Pressure At Admitted Emergency Room And Clinically Outcome In Acute Thrombotic Stroke Patients. *Malang Neurology Journal*; 2015. 1(2), 68–71. Retrieved on Feb 21, 2023. Available from: <https://mnj.ub.ac.id/index.php/mnj/article/view/41>
12. Keulen, S. A. M. T. Foreign Accent Syndrome: A Neurolinguistic Analysis. University of Groningen; 2017. Retrieved on Feb 21, 2023. Available from: <https://research.rug.nl/en/publications/foreign-accent-syndrome-a-neurolinguistic-analysis>
13. Olguner Eker O, Gultekin M, Demirel Ozsoy S. Foreign Accent Syndrome After COVID 19 Infection: A Case Report. *J Nerv Ment Dis*; 2023 Dec. 211(12):974-976. DOI: 10.1097/NMD.0000000000001617
14. Belyk, M., Brown, R., Beal, D. S., Roebroek, A., McGettigan, C., Guldner, S., & Kotz, S. A. Human larynx motor cortices coordinate respiration for vocal-motor control. *NeuroImage*; 2021. Retrieved on Feb 21, 2023. Available from: [www.elsevier.com/locate/neuroimage](http://www.elsevier.com/locate/neuroimage)
15. Oha, A., Duerden, E. G., & Pang, E. W. The role of the insula in speech and language processing. *Brain and Language*; 2014. 96–103. Retrieved on Feb 21, 2023. Available from: <https://ir.lib.uwo.ca/cgi/viewcontent.cgi?article=2200&context=paedpub>
16. Potgieser, A. R. E., de Jong, B. M., Wagemakers, M., Hoving, E. W., & Groen, R. J. M. Insights from the supplementary motor area syndrome in balancing movement initiation and inhibition. *Frontiers in Human Neuroscience*; 2014. 8(960). Retrieved on Feb 21, 2023. Available from: <https://doi.org/10.3389/fnhum.2014.00960>
17. Mavroudis I, Petridis F, Kazis D, et al. Foreign Accent Syndrome: insights from Neuroimaging and Pathophysiological mechanisms. *Acta Neurol Belg*; 2024 Nov. DOI: 10.1007/s13760-024-02690-y
18. Maeshima S, Osawa A. Memory Impairment Due to Stroke. In: *Stroke*. Exon Publications; 2021. 111–20. Retrieved on Feb 21, 2023. Available from: <https://exonpublications.com/index.php/exon/article/view/304>
19. Santosa, K. E., & Putra, S. D. Correlation between Neurological Deficits and Stroke Severity in Patients with Hemorrhagic Stroke at Dr. Sardjito Hospital Yogyakarta. *J Stroke*; 2019. 6(2):45–9. Retrieved on Feb 21, 2023. Available from: <https://journals.sagepub.com/doi/abs/10.1177/2324997619871229>
20. Panahi, Y., Alizadeh-Navaei, R., & Mirmiran, P. Cardiovascular Risk Factors in Stroke Patients: A Comprehensive Study. *Front Neurol*; 2020. 11:1525. Retrieved on Feb 21, 2023. Available from: <https://www.frontiersin.org/articles/10.3389/fneur.2020.01525/full>