Magna Neurologica Vol. 3, No. 1, January 2025

https://journal.uns.ac.id/magna-neurologica
DOI: 10.20961/magnaneurologica.v3i1.909
e-ISSN 2985-3729 p-ISSN 2963-6027

CASE REPORT **OPEN ACCESS**

MANAGEMENT OF PREOPERATIVE MENINGIOMA EMBOLISATION: FIRST CASE REPORT AT DR SOERADJI TIRTONEGORO HOSPITAL KLATEN

Fauzi Novia Isnaening Tyas[1*], Huda Syahdan Al Hadad[1], Adika Mianoki[2]

***Correspondence**: *fauzinoviapd@gmail.com*
[1]*Dr. RM. Soedjarwadi Psychiatric Hospital, Klaten, Indonesia*
[2]*Department of Neurology, Dr. Soeradji Tirtonegoro General Hospital, Klaten, Indonesia*

Article History:
Received: September10, 2023
Accepted: May 27, 2024
Published: January 1, 2025

Cite this as:
Tyas FNI, Hadad HSA, Mianoki A. Management of Preoperative Meningioma Embolisation: First Case Report at Dr Soeradji Tirtonegoro Hospital Klaten. Magna Neurologica. 3(1) January 2025: 23-27. 10.20961/magnaneurologica.v2i2.909

ABSTRACT

Background: Meningioma is the most common primary central nervous system tumor among benign brain tumors. Clinical manifestations vary based on the tumor's location and size, with some patients being asymptomatic and others experiencing neurological deficits. Symptomatic meningioma patients often undergo surgical management. Preoperative embolization has been shown to reduce surgical complications by minimizing intraoperative bleeding and shortening the procedure's duration.
Case: A 47-years-old woman presented with progressive right limb weakness, recurrent headaches, blurred vision, and vomiting over three months, worsening in the past week. Neurological examination revealed XII nerve paresis and limb weakness. Imaging studies identified a sizeable intracranial mass with perilesional edema, leading to a diagnosis of meningioma. The patient underwent preoperative endovascular embolization followed by craniotomy and tumor excision, resulting in a favorable postoperative outcome. Her postoperative course was uneventful, with significant improvement and regular follow-up at Dr. Soeradji Tirtonegoro General Hospital.
Discussions: Preoperative embolization is beneficial for selected patients with intracranial meningiomas, especially those with highly vascular tumors. This technique effectively reduces intraoperative bleeding and surgical duration, decreasing the risk of complications. Advances in embolization techniques and materials have significantly improved outcomes and expanded their applicability. Ongoing research continues to refine and optimize meningioma management, enhancing surgical success and patient prognosis.
Conclusion: This case demonstrates the effectiveness of preoperative embolization in managing intracranial meningiomas. The technique reduces intraoperative complications and improves postoperative recovery, emphasizing its critical role in optimizing surgical outcomes for meningioma patients.

Keywords: embolization, meningioma, neurointervention

This is an open access article distributed under the terms of the Creative Commons Attribution- 4.0 International License

Introduction

Meningioma is the most common primary central nervous system tumor, with a prevalence of approximately 37.6% of cases. Additionally, nearly half of all brain tumors are benign. Most meningiomas are benign, falling under the category of grade 1.[1,2] However, a small subset, around 1 to 3% of cases, may undergo malignant transformation, with a 5-year survival rate ranging from 32% to 64%. Several predisposing factors increase the risk of its occurrence, including genetic disorders such as neurofibromatosis type 2, radiation exposure, hormonal therapy, and family history.[1,3] The parasagittal region stands as the most common location for these tumors. Usually slow-growing, round (non-infiltrating), benign, and can be

Copyright © 2025 by Authors

asymptomatic.[1] Clinical manifestations depend on the location and size of the meningioma. Some patients may be asymptomatic, while others may have neurological deficits. A CT scan and MRI meningioma.[2,3]

Managing asymptomatic and slow-growing meningioma is observational, combined with routine imaging. However, cases involving rapidly growing or large tumors, as well as symptomatic patients, necessitate surgical intervention as the optimal management strategy. Preoperative embolization has demonstrated its utility in reducing intraoperative complications by minimizing bleeding and shortening surgical duration. There have been many advances due to the research conducted, which has the potential to change management in dealing with meningioma.[4,5] Based on the context above, the authors are inclined to delve into case studies focused on embolization management of meningioma at Dr. Soeradji Tirtonegoro Hospital.

Case Report

A 47-year-old woman with no prior medical history presented with complaints of symptoms of weakness in the right limbs and intermittent headaches over the past 3 months, which had worsened significantly in the last week. Symptoms are accompanied by blurred vision and vomiting. The patient denied experiencing seizures, reduced consciousness, stomach issues, hearing loss, or behavioral disorders. The patient also had no history of hypertension, diabetes mellitus, elevated cholesterol, heart disease, or stroke. However, the patient admitted a history of using injectable birth control. Based on the physical examination, the patient's general condition was moderate, composure with GCS E4V5M6, overweight with a height of 159 cm and a body weight of 68 kg. The patient's blood pressure is 140/80 mmHg, pulse rate at 80 beats per minute, respiratory rate at 20 times per minute, and body temperature at 36.7 degrees Celsius. The general status examination was within normal limits. Physical examination found both isochor pupils with a diameter of 3mm/3mm, normal light reflex, and normal corneal reflex. Examination of the cranial nerves revealed paresis of the right XII nerve. On examination of movement and strength, weakness in the right superior and inferior extremities was 333. Physiological and pathological reflexes were both found to be within normal limits.

Laboratory tests showed an elevated leukocyte count and positive HBsAg. Other laboratory results fell within normal ranges. A cerebral CT scan displayed cerebral edema and a sizeable intracranial mass with a rounded isodense lesion in the left cerebral hemisphere region, accompanied by perilesional edema and causing midline shift (Figure 1). For further characterization of this lesion, a brain MRI was performed. Brain MRI examination indicated an extra-axial mass in the left parietal region, which deviated the midline towards the right, narrowed the left lateral ventricle, and had left ACA A1 PCA P1 and right vertebral stenosis (Figure 2). Additionally, the patient underwent a cerebral Digital Subtraction Angiography (DSA) examination, which revealed the presence of a blush tumor located in the region of the left hemisphere. This tumor was found to receive its primary blood supply from the middle meningeal artery (MMA). Based on these findings, the results of the examination provided a definitive diagnosis of meningioma.

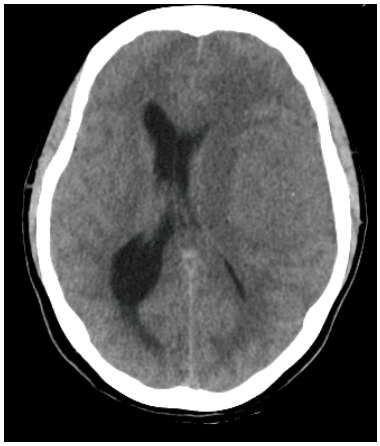

Figure 1. Axial cerebral preoperative CT scan showing an isodense lesion, rounded shape in the left cerebral hemisphere region with surrounding perifocal edema that makes a midline shift to the right. Note perilesional edema with mass effect on adjacent structures.

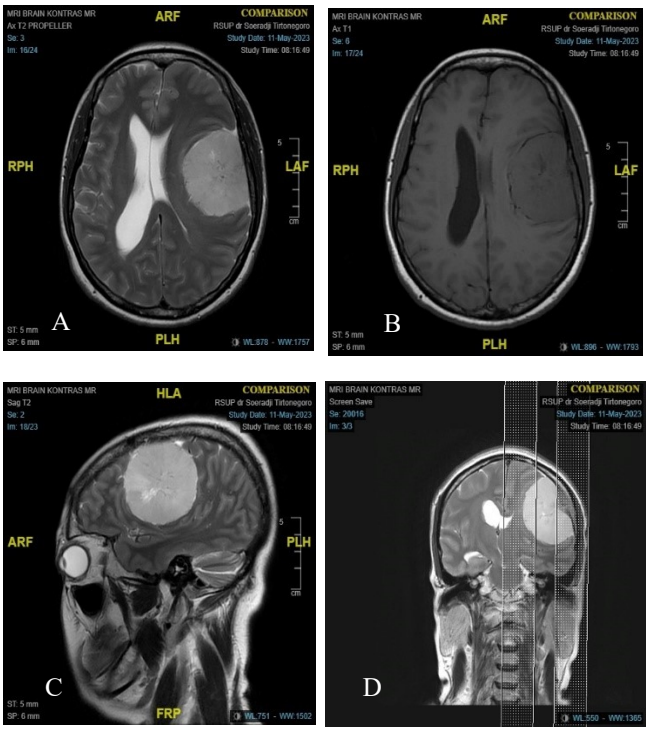

Copyright © 2025 by Authors

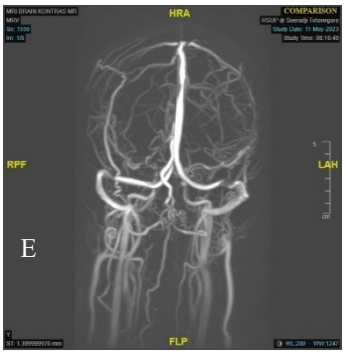

Figure 2. Brain MRI reveals an extra-axial lesion in the left parietal region (5.34 x 4.35 x 5.52 cm), rounded, well-defined, with isointense T1W, hyperintense T2W, nonrestricted DWI signals, and a 0.82 cm midline shift to the right. The left lateral ventricle appears narrowed. MRA & MRV (E) show stenosis in the left ACA A1, PCA P1, and right vertebral artery.

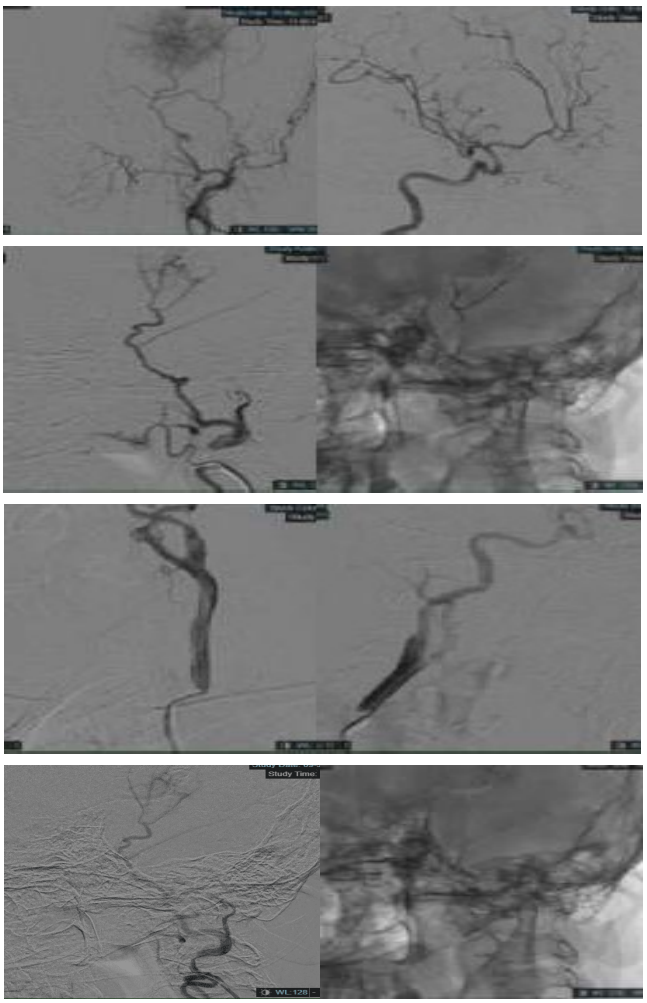

Figure 3. Multiple images of the AP and lateral ICA and ECA arteriograms of a patient with a left parietal meningioma. (A) AP and lateral right ICA injection images before embolization, Pre- embolization right ECA injection shows tumor swelling of the middle meningeal artery (B) Postembolization right ECA injection images reveal complete obliteration of tumor blush, main supply is from MMA—AP, anteroposterior; ECA, external carotid artery; ICA, internal carotid artery.

Management of meningioma in these patients is planned through a craniotomy procedure for tumor excision. To optimize the surgical process, a preoperative endovascular tumor embolization was performed (Figure 3). Then the patient underwent tumor excision surgery 3 days after embolization. Patients also received dexamethasone 5mg/1mL injection therapy, analgesic drugs, vitamin B complex, and symptomatic drugs.

Postoperatively, the patient's condition exhibited positive progress, with their health status being favorable. Regular follow-up visits are being conducted at Dr. Soeradji Tirtonegoro Klaten General Hospital to monitor and manage the patient's recovery process. The patient is scheduled for imaging re-evaluation 1 year after surgery in August 2024.

Discussion

Meningioma represents the most common benign intracranial neoplasm in adults, with a prevalence of 13 to 26% of primary intracranial tumors.[1] The annual incidence is approximately 2 to 7 in 100,000 for women and 1 to 5 in 100,000 for men.[2,7] There is a peak incidence in the fourth to sixth decades of life, with a notable estimated female-to-male predominance ratio of 2:1.[1,3]

Most meningiomas are sporadic, but some are associated with certain conditions and risk factors.[2] Various environmental factors, including obesity, alcoholism, exposure to ionizing radiation, radiotherapy, hormonal factors such as exposure to exogenous hormones, hormone replacement therapy, use of oral contraceptive pills, and breast cancer, have been identified as potential contributors to meningioma development.[2] There are no specific causes of meningioma, but certain risk factors have been identified. This patient has a history of injection contraceptive use. Meningiomas express progesterone, estrogen, and androgen receptors in their membranes.[2,3] Progesterone receptors can be found in 72% of tumors. The elevated incidence in women can primarily attributed to hormonal factors.[4]

While meningiomas have a slow growth rate, most patients will have less significant initial symptoms, including headache, pain, subtle personality changes (often diagnosed with dementia or depression), and, less commonly, seizures.[4] In this patient, the symptoms complained of were right limb weakness and dizziness.[5] Upper motor neuron signs commonly reported in intracranial meningioma include hypertonia or clonus, hyperreflexia, positive Babinski and Hoffman's signs, paresis, or paralysis. Other reported symptoms included anosmia, headache, dizziness, visual disturbances, seizures, papilledema,

Copyright © 2025 by Authors

and behavioral changes.[1,3] Patients with parasagittal meningioma and convexity of the brain may present with paresis or paralysis of the contralateral affected limb.[6]

The diagnosis of meningioma is established based on history, physical examination, and radiological examination.[2] Often, a meningioma on a non-contrast head CT scan appears as a hyperdense or isodense dura-based lesion.[6] The best radiological method for diagnosing meningioma is an MRI of the brain with contrast. Peritumoral cerebral edema, usually of the vasogenic type, may be present.[2,4] Brain edema generally occurs due to disruption of the blood-brain barrier.[1] This causes extracerebral protein-rich fluid to accumulate in the cerebral parenchyma, causing vasogenic edema. Brain MRI shows edema clearly as hyperintensity on T2-weighted images. Digital subtraction angiography (DSA) demonstrates a meningioma's feeding arteries and differentiates between pial and dural blood supplies.[7,8] The vascular supply to the meningioma is mainly via the dural meningeal artery and less frequently via the pial artery.[7] DSA is helpful for surgery in patients with giant meningioma. Preoperative tumor feeder embolization during DSA may aid surgical resection by reducing intraoperative bleeding and making the tumor more malleable.[7,8]

Management for meningioma is based primarily on symptoms. Meningiomas detected incidentally on imaging generally show slow growth or no symptoms.[9] For symptomatic meningioma, the treatment of choice is open surgical resection, which may be curative if complete resection can be achieved.[10] Potential advantages of preoperative embolization include reduced operative duration, reduced operative blood loss, and altered tumor consistency, reducing the technical difficulty of surgical resection and increasing the likelihood of achieving complete resection.[10,11] Embolization may cause histopathological changes within a meningioma, including necrosis, ischemic, and microvascular fibrinoid changes.[12] Hypoxia caused by impaired tumor blood supply also causes changes in protein expression consistent with angiogenesis and increased growth, together with cytologic changes, including macrophage infiltration.[8,10,12] Embolization is also accompanied by a risk of procedural complications, including excellent vessel dissection, microcatheter fracture, and accidental arterial or venous occlusion resulting in hemorrhagic or ischemic infarction. Preoperative meningioma embolization is often performed before surgical excision.[8,13] Preoperative meningioma embolization aims to reduce tumor blood flow by eliminating one (or more) arterial feeders to the tumor.[9] Proponents of preoperative embolization argue that it reduces intraoperative blood loss, transfusion requirements, and overall surgical time and makes the tumor softer, making the procedure easier and safer.[14,15] Some authors suggest that embolization may reduce tumor recurrence or be used as a stand-alone therapy in high-risk surgical candidates.

In this case, the option to undergo embolization before resection of meningioma during the procedure offers benefits such as reduced tumor vascularity, facilitating smoother resection, and potentially shortening hospital stays.[15] This is also supported by Macpherson's reported personal experience with 28 embolized and 24 non-embolized meningiomas.[16,17] Results indicate reduced blood loss and surgical complications with better outcomes, along with subjective reports of easier surgery, according to neurosurgeons.[16] The overall complication rate was 21% in the preoperative embolization group compared to 58% in the operation-only group.[17,18] Meningioma devascularization is most effective directly after embolization, with subsequent benefits gradually diminishing over time.[18,19] To reduce the risk of tumor revascularization, performing resection within 7 days post-embolization is recommended, as prolonged delays may lead to collateralization and reclassification, reducing surgical outcomes. In this patient, resection was performed 3 days after embolization. The patient's condition improved after the surgery; a follow-up examination is planned for 1 year.

Intracranial meningioma embolization has historically been used as a preoperative strategy that has resulted in better surgical outcomes for larger tumors.[20] However, the risks, including stroke, hemorrhage, edema, cranial nerve deficits, and blindness, cannot be discounted, and a thorough discussion of the benefits versus risks of this procedure must be undertaken with a multidisciplinary approach.[21,22] Operators performing embolization procedures must be aware of the dangers.

Conclusion

In conclusion, this case highlights the efficacy of preoperative embolization as a valuable adjunctive therapy in managing intracranial meningiomas. By reducing intraoperative complications such as bleeding and surgical duration, preoperative embolization enhances the safety and success of surgical resection. Furthermore, the case underscores the importance of comprehensive neurological assessment and imaging studies in the timely diagnosis and treatment of meningiomas. As advancements in research continue to refine our understanding and treatment approaches, the future holds promise for further optimizing the management of meningiomas, ultimately improving patient outcomes and quality of life.

Copyright © 2025 by Authors

Acknowledgment

We thank the relevant respondents who were the subject of the case report writing.

References

1. Buerki, R.A.; Horbinski, C.M; Kruser, T; et al. An overview of meningiomas. Future Oncol; 2018. 14: 2161–2177. DOI: 10.2217/fon-2018-0006
2. Ogasawara, C; Philbrick, B.D; Adamson, D.C. Meningioma: A Review of Epidemiology, Pathology, Diagnosis, Treatment, and Future Directions. Biomedicines; 2021. 9: 319. DOI: 10.3390/biomedicines9030319
3. Bukovac, Anja, et al. Bilateral Meningioma: A Case Report and Review of the Literature. International Journal of Molecular Sciences; 2022. 3: 1187. DOI: 10.3390/ijms23031187
4. Friconnet, Guillaume, et al. Pre-surgical embolization of intracranial meningioma with Onyx: A safety and efficacy study. Journal of Neuroradiology; 2020. 5: 353-357. DOI: 10.1016/j.neurad.2020.03.002
5. Barros, Guilherme, et al. Predictors of preoperative endovascular embolization of meningiomas: subanalysis of anatomic location and arterial supply. Journal of NeuroInterventional Surgery; 2020. 2:204-208. DOI: 10.1136/neurintsurg-2019-015188
6. Chen, Lei, et al. Preoperative embolization versus direct surgery of meningiomas: a meta-analysis. World Neurosurgery; 2019. 128: 62-68. DOI: 10.1016/j.wneu.2019.04.225
7. Dabus, Guilherme; Linfante, Italo; et al. Angiography and embolization of meningiomas. In: Handbook of Clinical Neurology. Elsevier; 2020. 193-202. DOI: 10.1016/B978-0-12-804824-3.00013-0
8. Bukovac, Anja, et al. Bilateral meningioma: a case report and review of the literature. International journal of molecular sciences; 2022. 3: 1187. DOI: 10.3390/ijms23031187
9. Ilyas, Adeel, et al. Preoperative embolization of skull base meningiomas: a systematic review. Journal of Clinical Neuroscience; 2019. p. 259-264. DOI: 10.1016/j.jocn.2019.01.002
10. Yoon, Nam, et al. Preoperative embolization of skull base meningiomas: indications, techniques, and complication avoidance. Neurosurg Focus; 2018. 44 (4): E5. DOI: 10.3171/2018.1.FOCUS17752
11. Abdel Khalek, Ahmed Rizk, et al. The Impact of Preoperative Endovascular Embolization of Intracranial Meningiomas on Surgical Outcome. Benha Medical Journal; 2021. 3: 794-810. DOI: 10.21608/bmfj.2021.191726
12. Toader, Corneliu, et al. Successful Surgical Treatment of a Giant Intraventricular Meningioma: A Case Report and Literature Review. Medicina; 2024. 4: 560. DOI: 10.3390/medicina60040560
13. Brandel, Michael G., et al. Impact of preoperative endovascular embolization on immediate meningioma resection outcomes. Neurosurgical focus; 2018. 4: E6. DOI: 10.3171/2018.1.FOCUS17753
14. Schartz, Derrek, et al. Preoperative Embolization of Meningiomas Facilitates Reduced Surgical Complications and Improved Clinical Outcomes: A Meta-analysis of Matched Cohort Studies. Clinical Neuroradiology; 2023. 3: 755-762. DOI: 10.1007/s00062-022-01189-0
15. Batista, Sávio, et al. Enhancing meningioma resection: a comprehensive study on the safety and effectiveness of Onyx™ presurgical embolization. Neurosurgical Review; 2023. 1: 299. DOI: 10.1007/s10143-022-01788-0
16. Onyinzo, Christina, et al. Safety and Efficacy of Preoperative Embolization in Giant Intracranial Meningiomas Compared with Resection Surgery Alone. Archives of Neuroscience; 2024. p. 1. DOI: 10.5812/ans-142629
17. Balaha, Ahmed Mohammed; Ganna, et al. Preoperative Embolization of Skull Base Meningiomas: Impact on surgical results. Pan Arab Journal of Neurosurgery; 2021. 2: 42-47. DOI: 10.21608/pajn.2021.81297.1025
18. Yildiz, B., & Soylemez, B. Preoperative embolization of meningiomas: Single center. Annals of Medical Research: 2021. 28(10), 1815–1819. Retrieved on Mar 24, 2023. Available from: https://annalsmedres.org/index.php/aomr/article/view/3932
19. Goldbrunner, Roland, et al. EANO guideline on the diagnosis and management of meningiomas. Neuro-oncology; 2021. 1: 1821-1834. DOI: 10.1093/neuonc/noab150
20. Akimoto, Taisuke, et al. Preoperative tumor embolization and meningioma recurrence: A retrospective analysis. J NeuroIntervent Surg; 2023. 8: 814-820. DOI: 10.1136/neurintsurg-2023-019456
21. Jumah, Fareed, et al. Does preoperative embolization improve outcomes of meningioma resection? A systematic review and meta-analysis. Neurosurgical Review; 2021. 3151-3163. DOI: 10.1007/s10143-021-01513-3
22. Khan, Awais Ali, et al. The Pre-operative Embolization of Meningioma Leads to Reduced Operating Time and Less Intraoperative Bleeding. Pakistan Armed Forces Medical Journal; 2023. 3: 905-08. DOI: 10.51253/pafmj.v73i3.8978

Copyright © 2025 by Authors